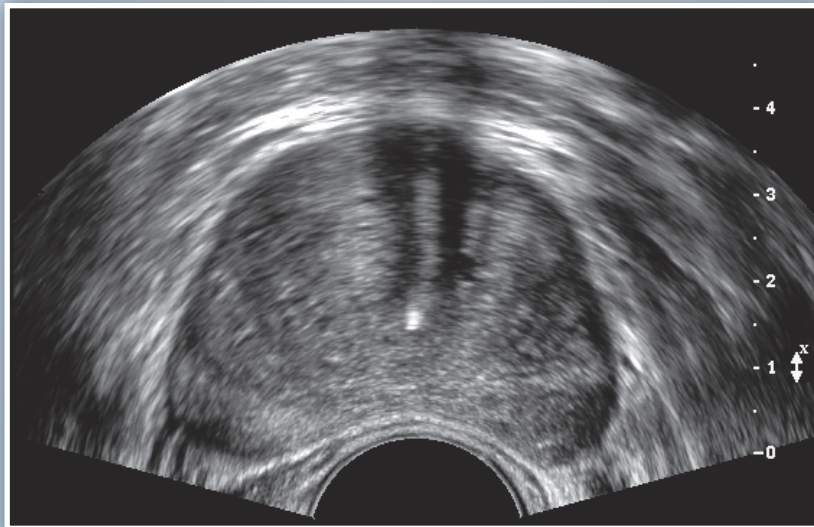


AIUM Practice Parameter for the Performance of an

Ultrasound Examination in the Practice of Urology

Parameter developed in collaboration with the American Urological Association.



The American Institute of Ultrasound in Medicine (AIUM) is a multidisciplinary association dedicated to advancing the safe and effective use of ultrasound in medicine through professional and public education, research, development of parameters, and accreditation. To promote this mission, the AIUM is pleased to publish, in conjunction with the American Urological Association (AUA), this *AIUM Practice Parameter for the Performance of an Ultrasound Examination in the Practice of Urology*. We are indebted to the many volunteers who contributed their time, knowledge, and energy to bringing this document to completion.

The AIUM represents the entire range of clinical and basic science interests in medical diagnostic ultrasound, and, with hundreds of volunteers, the AIUM has promoted the safe and effective use of ultrasound in clinical medicine for more than 50 years. This document and others like it will continue to advance this mission.

Practice parameters of the AIUM are intended to provide the medical ultrasound community with parameters for the performance and recording of high-quality ultrasound examinations. The parameters reflect what the AIUM considers the minimum criteria for a complete examination in each area but are not intended to establish a legal standard of care. AIUM-accredited practices are expected to generally follow the parameters with recognition that deviations from these parameters will be needed in some cases, depending on patient needs and available equipment. Practices are encouraged to go beyond the parameters to provide additional service and information as needed.



14750 Sweitzer Ln, Suite 100
Laurel, MD 20707-5906 USA
800-638-5352 • 301-498-4100
www.aium.org

I. Introduction

The clinical aspects of this parameter (Introduction, Specifications for Individual Examinations, and Equipment Specifications) were developed collaboratively by the American Institute of Ultrasound in Medicine (AIUM) and the American Urological Association (AUA). Several sections of this parameter (Qualifications and Responsibilities of Personnel, Documentation, and Quality Control and Improvement, Safety, Infection Control, and Patient Education Concerns) vary between the organizations and are addressed by each separately.

This parameter has been developed to assist practitioners performing an ultrasound examination in the practice of urology. While it is not possible to detect every abnormality, adherence to the following parameters will maximize the probability of answering the clinical question prompting the study.

II. Qualifications and Responsibilities of Personnel

See www.aium.org for AIUM Official Statements including *Standards and Guidelines for the Accreditation of Ultrasound Practices* and relevant Physician Training Guidelines.

III. Specifications for Individual Examinations

Doppler ultrasound may be useful to differentiate vascular from nonvascular structures in any location. Measurements should be considered for any abnormal area.

A. Kidney and/or Bladder

1. Indications

Indications for an ultrasound examination of the kidney and/or bladder include but are not limited to:

- Flank and/or back pain;
- Signs or symptoms that may be referred from the kidney and/or bladder regions such as hematuria;
- Abnormal laboratory values or abnormal findings on other imaging examinations suggestive of kidney and/or bladder pathology;
- Follow-up of known or suspected abnormalities in the kidney and/or bladder;
- Evaluation of suspected congenital abnormalities;
- Abdominal trauma;
- Pretransplantation and posttransplantation evaluation; and
- Planning and guidance for an invasive procedure.

2. Specifications for a Kidney Examination

The examination should include long-axis and transverse views of the upper poles, midportions, and lower poles of the kidneys. The cortex and renal pelvises should be assessed. A maximum measurement of renal length should be recorded for both kidneys. Decubitus, prone, or upright positioning may provide better images of the kidneys. When possible, renal echogenicity should be compared to echogenicity of the adjacent liver or spleen. The kidneys and perirenal regions should be assessed for abnormalities.

For vascular examination of the kidneys, Doppler imaging can be used:

1. To assess renal arterial and venous patency; and
2. To evaluate adults suspected of having renal artery stenosis. For this application, angle-adjusted measurements of the peak systolic velocity should be made proximally, centrally, and distally in the extrarenal portion of the main renal arteries when possible. The peak systolic velocity of the adjacent aorta (or iliac artery in transplanted kidneys) should also be documented for calculating the ratio of the renal to aortic peak systolic velocity. Spectral Doppler evaluation of the intrarenal arteries from the upper and lower portions of the kidneys, performed to evaluate the early systolic peak, may be of value as indirect evidence of proximal stenosis in the main renal artery.

3. Urinary Bladder and Adjacent Structures

When performing a complete ultrasound evaluation of the urinary tract, transverse and longitudinal images of the distended urinary bladder and its wall should be included, if possible. Bladder lumen or wall abnormalities should be noted. Dilatation or other distal ureteral abnormalities should be documented. Transverse and longitudinal scans may be used to demonstrate any postvoid residual, which may be quantitated and reported.

4. Equipment Specifications

Kidney and/or bladder ultrasound studies should be conducted with real-time scanners, preferably using sector or linear (straight or curved) transducers. The equipment should be adjusted to operate at the highest clinically appropriate frequency, realizing that there is a trade-off between resolution and beam penetration. For most preadolescent pediatric patients, mean frequencies of 5 MHz or greater are preferred, and in neonates and small infants, a higher-frequency transducer is often necessary. For adults, mean frequencies between 2 and 5 MHz are most commonly used. When Doppler studies are performed, the Doppler frequency may differ from the imaging frequency. Diagnostic information should be optimized while keeping total ultrasound exposure as low as reasonably achievable.

Suggested Reading

1. Babcock DS, Patriquin HB. The pediatric kidney and adrenal glands. In: Rumack CM, Wilson SR, Charboneau JW, et al (eds). *Diagnostic Ultrasound*. 3rd ed. Philadelphia, PA: Elsevier Mosby; 2005:1905–1940.
2. Baxter GM. Imaging in renal transplantation. *Ultrasound Q* 2003; 19:123–138.
3. Hagen-Ansert SL. Introduction to abdominal scanning techniques and protocols. In: Hagen-Ansert SL (ed). *Textbook of Diagnostic Ultrasonography*. 5th ed. St Louis, MO: CV Mosby Co; 2001:42–69.

4. Middleton WD, Kurtz AB, Hertzberg BS. Kidney. In: *Ultrasound: The Requisites*. 2nd ed. St Louis, MO: CV Mosby Co; 2004:103–151.
5. Muradali D, Wilson SR. Organ transplantation. In: Rumack CM, Wilson SR, Charboneau JW, et al (eds). *Diagnostic Ultrasound*. 3rd ed. Philadelphia, PA: Elsevier Mosby; 2005:675–704.
6. Siegel MJ. Urinary tract. In: Siegel MJ (ed). *Pediatric Sonography*. 3rd ed. Philadelphia, PA: Lippincott Williams & Wilkins; 2001:385–473.
7. Thurston W, Wilson SR. The urinary tract. In: Rumack CM, Wilson SR, Charboneau JW, et al (eds). *Diagnostic Ultrasound*. 3rd ed. Philadelphia, PA: Elsevier Mosby; 2005:321–394.

B. Prostate

1. Indications

Indications for a prostate ultrasound examination include but are not limited to:

- Guidance for biopsy in the presence of abnormal digital rectal examination findings or an elevated prostate-specific antigen level;
- Assessment of gland and prostate volume before medical, surgical, or radiation therapy;
- Symptoms of prostatitis with a suspected abscess;
- Assessment of congenital anomalies;
- Infertility; and
- Hematospermia.

2. Specifications of the Prostate Ultrasound Examination

The following parameters describe the examination of the prostate and surrounding structures:

a. Prostate

The prostate should be imaged in its entirety in at least 2 orthogonal planes, sagittal and axial or longitudinal and coronal, from the apex to the base of the gland. An estimated volume is determined from measurements in 3 orthogonal planes (volume = length × height × width × 0.52). The volume of the prostate may be correlated with the prostate-specific antigen level.

The gland should be evaluated for a focal mass, echogenicity, symmetry, and continuity of margins. Color and power Doppler sonography may be helpful in detecting areas of increased vascularity that can be used to select potential sites for biopsy.

The periprostatic fat and neurovascular bundle should be evaluated for symmetry and echogenicity. The course of the prostatic urethra should be documented, when possible, and asymmetry between left and right periurethral tissues as well as their impact on the base of the bladder should be noted.

b. Seminal Vesicles, Vasa Deferentia, and Perirectal Space

The seminal vesicles should be evaluated for size, shape, position, symmetry, and echogenicity from their insertion into the prostate via the ejaculatory ducts to their cranial and lateral extents. Particular attention should be given to the normal taper-

ing of the seminal vesicle as it joins the prostate. In patients being evaluated for infertility, the vasa deferentia must be evaluated. The presence and size of seminal vesicle, ejaculatory, müllerian, or utricle cysts or evidence of seminal vesicle or ejaculatory duct obstruction should be noted. Inclusion of the anterior perirectal space, in particular the region that abuts the prostate and perirectal tissues, is important.

3. Equipment Specifications

A prostate ultrasound examination should be conducted with a real-time transrectal (also termed endorectal) transducer using the highest clinically appropriate frequency, realizing that there is a trade-off between resolution and beam penetration. With modern equipment, these frequencies are usually 6 MHz or higher. A lower frequency may be necessary for transabdominal and transperineal examinations.

See the AIUM Official Statement *Guidelines for Cleaning and Preparing External- and Internal-Use Ultrasound Probes Between Patients*.

Suggested Reading

1. Basillote JB, Armenakas NA, Hochberg DA, Fracchia JA. Influence of prostate volume in the detection of prostate cancer. *Urology* 2003; 61:167–171.
2. Clements R. The role of transrectal ultrasound in diagnosing prostate cancer. *Curr Urol Rep* 2002; 3:194–200.
3. Dubinsky TJ, Cuevas C, Dighe MK, Kolokythas O, Hwang JH. High-intensity focused ultrasound: current potential and oncologic applications. *AJR Am J Roentgenol* 2008; 190:191–199.
4. Galosi AB, Montironi R, Fabiani A, Lacetera V, Galle G, Muzzonigro G. Cystic lesions of the prostate gland: an ultrasound classification with pathological correlation. *J Urol* 2009; 181:647–657.
5. Halpern EJ. Anatomy of the prostate gland. In: Halpern EJ, Cochlin LI, Goldberg BB (eds). *Imaging of the Prostate*. London, England: Martin Dunitz Ltd; 2002.
6. Halpern EJ. Color and power Doppler evaluation of the prostate. In: Halpern EJ, Cochlin LI, Goldberg BB (eds). *Imaging of the Prostate*. London, England: Martin Dunitz Ltd; 2002.
7. Halpern EJ. Ultrasound-guided biopsy of the prostate. In: Halpern EJ, Cochlin LI, Goldberg BB (eds). *Imaging of the Prostate*. London, England: Martin Dunitz Ltd; 2002.
8. Halpern EJ. Measurement of the prostate gland. In: McGahan J, Goldberg BB (eds). *Atlas of Ultrasound Measurements*. 2nd ed. Chicago, IL: Mosby Year Book; 2005.
9. Halpern EJ, Frauscher F, Strup SE, Nazarian LN, O’Kane P, Gomella LG. Prostate: high-frequency Doppler US imaging for cancer detection. *Radiology* 2002; 225:71–77.
10. Halpern EJ, Strup SE. Using gray-scale and color and power Doppler sonography to detect prostatic cancer. *AJR Am J Roentgenol* 2000; 174:623–627.
11. Hittelman AB, Purohit RS, Kane CJ. Update of staging and risk assessment for prostate cancer patients. *Curr Opin Urol* 2004; 14:163–170.
12. Hricak H, Choyke PL, Eberhardt SC, Leibel SA, Scardino PT. Imaging prostate cancer: a multidisciplinary perspective. *Radiology* 2007; 243:28–53.
13. Kim SH, Kim SH. Correlations between the various methods of estimating prostate volume: transabdominal, transrectal, and three-dimensional US. *Korean J Radiol* 2008; 9:134–139.

14. Kirkham AP, Emberton M, Hoh IM, Illing RO, Freeman AA, Allen C. MR imaging of prostate after treatment with high-intensity focused ultrasound. *Radiology* 2008; 246:833–844.
15. Kundra V, Silverman PM, Matin SF, Choi H. Imaging in oncology from the University of Texas M. D. Anderson Cancer Center: diagnosis, staging, and surveillance of prostate cancer. *AJR Am J Roentgenol* 2007; 189:830–844.
16. La Vignera S, Calogero AE, Arancio A, Castiglione R, De Grande G, Vicari E. Transrectal ultrasonography in infertile patients with persistently elevated bacteriospermia. *Asian J Androl* 2008; 10:731–740.
17. Ozden E, Turgut AT, Yaman O, Gulpinar O, Baltaci S. Follow-up of the transrectal ultrasonographic features of the prostate after biopsy: does any ultrasonographically detectable lesion form secondary to the first biopsy? *J Ultrasound Med* 2005; 24:1659–1663.
18. Sedelaar JP, De La Rosette JJ, Beerlage HP, Wijkstra H, Debruyne FM, Aarnink RG. Transrectal ultrasound imaging of the prostate: review and perspectives of recent developments. *Prostate Cancer Prostatic Dis* 1999; 2:241–252.
19. Vo T, Rifkin MD, Peters TL. Should ultrasound criteria of the prostate be redefined to better evaluate when and where to biopsy? *Ultrasound Q* 2001; 17:171–176.
20. Wasserman NF. Benign prostatic hyperplasia: a review and ultrasound classification. *Radiol Clin North Am* 2006; 44:689–710, viii.
21. Zalesky M, Urban M, Smerhovsky Z, Zachoval R, Lukes M, Heracek J. Value of power Doppler sonography with 3D reconstruction in preoperative diagnostics of extraprostatic tumor extension in clinically localized prostate cancer. *Int J Urol* 2008; 15:68–75.

C. Scrotal

1. Indications

Indications for a scrotal ultrasound examination include but are not limited to:

- Evaluation of scrotal pain, including but not limited to testicular trauma, ischemia/torsion, and infectious or inflammatory scrotal disease;
- Evaluation of palpable inguinal, scrotal, or scrotal masses;
- Evaluation of scrotal asymmetry, swelling, or enlargement;
- Evaluation of potential scrotal hernias;
- Detection/evaluation of varicoceles;
- Evaluation of male infertility;
- Follow-up of prior indeterminate scrotal ultrasound findings;
- Localization of undescended testes;
- Detection of occult primary tumors in patients with metastatic germ cell tumors;
- Follow-up of patients with prior primary testicular neoplasms, leukemia, or lymphoma;
- Evaluation of abnormalities noted on other imaging studies (including but not limited to computed tomography, magnetic resonance imaging, and positron emission tomography); and
- Evaluation of intersex conditions.

2. Specifications of the Examination

The testes should be evaluated in at least 2 planes: longitudinal and transverse. Transverse images should be obtained in the superior, mid, and inferior portions of the testes. Longitudinal views should be obtained centrally as well as medially and laterally. Each testis should be evaluated in its entirety, as should the epididymis (head, body, and tail) when technically feasible. The size and echogenicity of each testis and epididymis should be compared to the contralateral side. Comparison of the testes, including gray scale and color Doppler imaging, is best accomplished with a side-by-side transverse image. Scrotal skin thickness should be evaluated. If a palpable abnormality is the indication for the sonogram, this area should be directly imaged.

Relevant extratesticular structures should be evaluated. Additional techniques such as the Valsalva maneuver and upright positioning can be used as needed. Any abnormality should be documented.

Doppler sonography (spectral and color/power Doppler imaging) should be used as necessary in all examinations of the scrotum, particularly in the setting of acute scrotal pain. If used, color and/or power Doppler sonography should include at least 1 side-by-side image comparing both testes and 2 images with identical Doppler settings to evaluate symmetry of flow. Low-flow detection settings should be used to document testicular blood flow, and the transducer frequency should be optimized for maximum Doppler sensitivity while maintaining adequate penetration. If flow cannot be demonstrated on color Doppler imaging, power Doppler imaging, if available, should be used to increase flow sensitivity.

3. Equipment Specifications

Scrotal studies should be conducted with a real-time scanner, preferably using a 7- to 14-MHz linear array transducer. A curvilinear or vector transducer with lower frequencies may be needed if the scrotum is enlarged, recognizing that there is a trade-off between resolution and beam penetration. The highest possible Doppler frequencies (typically in the 5- to 10-MHz range) providing optimal resolution and flow detection should be used. The Doppler frequency may differ from the imaging frequency. Standoff pads can be used, if necessary, to improve imaging.

Suggested Reading

1. Akin EA, Khati NJ, Hill MC. Ultrasound of the scrotum. *Ultrasound Q* 2004; 20:181–200.
2. Baldisserotto M, de Souza JC, Pertence AP, Dora MD. Color Doppler sonography of normal and torsed testicular appendages in children. *AJR Am J Roentgenol* 2005; 184:1287–1292.
3. Basu S, Howlett DC. High-resolution ultrasound in the evaluation of the nonacute testis. *Abdom Imaging* 2001; 26:425–432.
4. Bhatt S, Dogra VS. Role of US in testicular and scrotal trauma. *Radiographics* 2008; 28:1617–1629.
5. Casalino DD, Kim R. Clinical importance of a unilateral striated pattern seen on sonography of the testicle. *AJR Am J Roentgenol* 2002; 178:927–930.
7. Dogra VS, Bhatt S. Acute painful scrotum. *Radiol Clin North Am* 2004; 42:349–363.
8. Dogra VS, Gottlieb RH, Oka M, Rubens DJ. Sonography of the scrotum. *Radiology* 2003; 227:18–36.

9. Dogra VS, Rubens DJ, Gottlieb RH, Bhatt S. Torsion and beyond: new twists in spectral Doppler evaluation of the scrotum. *J Ultrasound Med* 2004; 23:1077–1085.
10. Gorman B, Carroll BA. Scrotal sonography. In: Rumack CM, Wilson SR, Charboneau JW (eds). *Diagnostic Ultrasound*. 3rd ed. Chicago, IL: CV Mosby Co; 2005:849–888.
11. Hörmann M, Balassy C, Philipp MO, Pumberger W. Imaging of the scrotum in children. *Eur Radiol* 2004; 14:974–983.
12. Karmazyn B, Steinberg R, Kornreich L, et al. Clinical and sonographic criteria of acute scrotum in children: a retrospective study of 172 boys. *Pediatr Radiol* 2005; 35:302–310.
13. Ragheb D, Higgins JR Jr. Ultrasonography of the scrotum: technique, anatomy, and pathologic entities. *J Ultrasound Med* 2002; 21:171–185.
14. Sudakoff GS, Quiroz F, Karcaaltincaba M, Foley WD. Scrotal ultrasonography with emphasis on the extratesticular space: anatomy, embryology, and pathology. *Ultrasound Q* 2002; 18:255–273.
15. Woodward PJ, Sohaey R, O'Donoghue MJ, Green DE. From the archives of the AFIP: tumors and tumorlike lesions of the testis—radiologic-pathologic correlation. *Radiographics* 2002; 22:189–216.
16. Yang DM, Kim SH, Kim HN, et al. Differential diagnosis of focal epididymal lesions with gray scale sonographic, color Doppler sonographic, and clinical features. *J Ultrasound Med* 2003; 22:135–142.

D. Penile

1. Indications

Indications for a penile ultrasound examination include but are not limited to:

- Evaluation of erectile dysfunction;
- Evaluation of priapism;
- Evaluation of dorsal vein thrombosis;
- Evaluation of penile fibrosis and penile curvature;
- Evaluation of abnormal findings on physical examination of the phallus or urethra;
- Evaluation of penile tumors;
- Evaluation of a urethral stricture, diverticulum, or cyst;
- Evaluation of a calculus or foreign body of the phallus or urethra; and
- Evaluation of penile trauma.

2. Specifications of the Examination

The phallus should be evaluated in at least 2 planes: longitudinal and transverse. Ventral and/or dorsal placement of the transducer should be used to obtain the best visualization of the corporal bodies and urethra. Urethral examinations might require a water-soluble intraurethral gel for detection of luminal and/or urethral wall pathology. Transverse images should be obtained in the proximal, mid, and distal portions of the external portion of the phallus. Longitudinal views of the external portion of the phallus should be obtained of the right and left corpora cavernosa including the cavernosal artery. The nonexternal portions of the corpora cavernosa and urethra might best be visualized by perineal placement of the transducer. The evaluation of corporal vascular integrity requires the use of color and spectral Doppler imaging. Evaluation for erectile dysfunction

requires the use of color and spectral Doppler imaging before and after pharmacostimulation. Use of pharmacostimulation should be done only after a discussion with the patient regarding the risks and benefits of the procedure and the potential for priapism. Complete detumescence is necessary at the end of the examination when pharmacostimulation is used. Vascular integrity is documented by following the change in vascular measurements at discrete time intervals. Documentation of these results should be recorded on each image acquired. The size and echogenicity of each corpus cavernosum should be compared to the contralateral side. If a palpable abnormality is the indication for the sonogram, this area should be directly imaged. Any abnormality should be documented.

3. Equipment Specifications

Penile studies should be conducted with a real-time scanner, preferably using frequencies greater than 10 MHz with a linear array transducer. The highest possible Doppler frequencies (typically greater than 10 MHz) providing optimal resolution and flow detection should be used. The Doppler frequency may differ from the imaging frequency.

Suggested Reading

1. Bassiouny HS, Levine LA. Penile duplex sonography in the diagnosis of venogenic impotence. *J Vasc Surg* 1991; 13:75–82.
2. Bearcroft PW, Berman LH. Sonography in the evaluation of the male anterior urethra. *Clin Radiol* 1994; 49:621–626.
3. Benson CB, Aruny JE, Vickers MA Jr. Correlation of duplex sonography with arteriography in patients with erectile dysfunction. *AJR Am J Roentgenol* 1993; 160:71–73.
4. Broderick GA, Lue TF. The penile blood flow study: evaluation of vasculogenic impotence. In: Jonas U, Thon W, F Stief CG (eds). *Erectile Dysfunction*. Berlin, Germany: Springer-Verlag; 1991.
5. Chou YH, Tiu CM, Pan HB, et al. High-resolution real-time ultrasound in Peyronie's disease. *J Ultrasound Med* 1987; 6:67–70.
6. Choudhary S, Singh P, Sundar E, Kumar S, Sahai A. A comparison of sonourethrography and retrograde urethrography in evaluation of anterior urethral strictures. *Clin Radiol* 2004; 59:736–742.
7. Kadioğlu A, Tefekli A, Erol H, Cayan S, Kandirali E. Color Doppler ultrasound assessment of penile vascular system in men with Peyronie's disease. *Int J Impot Res* 2000; 12:263–267.
8. Kim B, Kawashima A, LeRoy AJ. Imaging of the male urethra. *Semin Ultrasound CT MR* 2007; 28:258–273.
9. King BF, Lewis RW, McKusick MA. Evaluation of impotence. In: Bennett AH (ed). *Impotence: Diagnosis and Management of Erectile Dysfunction*. Philadelphia, PA: WB Saunders Co; 1994.
10. Morey AF, McAninch JW. Sonographic staging of anterior urethral strictures. *J Urol* 2000; 163:1070–1075.
11. Patel U, Lees WR. Penile sonography. In: Solibati L, Rizzato G (eds). *Ultrasound of Superficial Structures*. London, England: Churchill Livingstone; 1995:229–242.
12. Quam, J P, King, B F, James, E M et al: Duplex and color Doppler sonographic evaluation of vasculogenic impotence. *AJR Am J Roentgenol* 1989; 153:1141–1147.

13. Wilkins CJ, Sidhu PS. Diseases of the penis with functional evaluation. In: Baxter GM, Sidhu PS (eds). *Ultrasound of the Urogenital System*. Stuttgart, Germany: Georg Thieme Verlag; 2006.
14. Wilkins CJ, Sriprasad S, Sidhu PS. Colour Doppler ultrasound of the penis. *Clin Radiol* 2003; 58:514–523.

IV. Documentation

Adequate documentation is essential for high-quality patient care. There should be a permanent record of the ultrasound examination and its interpretation. Images of all appropriate areas, both normal and abnormal, should be recorded. Variations from normal size should be accompanied by measurements. Images should be labeled with the patient identification, facility identification, examination date, and side (right or left) of the anatomic site imaged. An official interpretation (final report) of the ultrasound findings should be included in the patient's medical record. Retention of the ultrasound examination should be consistent both with clinical needs and with relevant legal and local health care facility requirements.

Reporting should be in accordance with the *AIUM Practice Parameter for Documentation of an Ultrasound Examination*.

V. Quality Control and Improvement, Safety, Infection Control, and Patient Education Concerns

Policies and procedures related to quality control, patient education, infection control, and safety should be developed and implemented in accordance with the *AIUM Standards and Guidelines for the Accreditation of Ultrasound Practices*.

Equipment performance monitoring should be in accordance with the *AIUM Standards and Guidelines for the Accreditation of Ultrasound Practices*.

VI. ALARA Principle

The potential benefits and risks of each examination should be considered. The ALARA (as low as reasonably achievable) principle should be observed when adjusting controls that affect the acoustic output and by considering transducer dwell times. Further details on ALARA may be found in the AIUM publication *Medical Ultrasound Safety, Third Edition*.

Acknowledgments

This parameter was developed by the American Institute of Ultrasound in Medicine (AIUM) in collaboration with the American Urological Association (AUA) according to the process described in the AIUM *Clinical Standards Committee Manual*.

Collaborative Subcommittees

AIUM

Pat F. Fulgham, MD, *Chair*

Bruce R. Gilbert, MD, PhD

Harvey L. Nisenbaum, MD

Alan J. Wein, MD, PhD

AUA

Christopher R. Porter, MD

Karen C. Baker, MD

Frederick A. Gulmi, MD

AIUM Clinical Standards Committee

Leslie Scoutt, MD, *Chair*

Joseph Wax, MD, *Vice Chair*

Harris L. Cohen, MD

Lin Diacon, MD, RDMS, RPVI

J. Christian Fox, MD, RDMS

Pat Fulgham, MD

Charlotte Henningsen, MS, RT, RDMS, RVT

Adam Hiett, MD, RDMS

Lars Jensen, MD

Anthony Odibo, MD, MSCE

Steven Perlmutter, MD

Olga Rasmussen, RDMS

Deborah Rubens, MD

Khaled Sakhel, MD

Shia Salem, MD

Jay Smith, MD

Lami Yeo, MD

Original copyright 2011

Renamed 2015