AIUM Practice Parameter for the Performance of

Selected Ultrasound-Guided Procedures

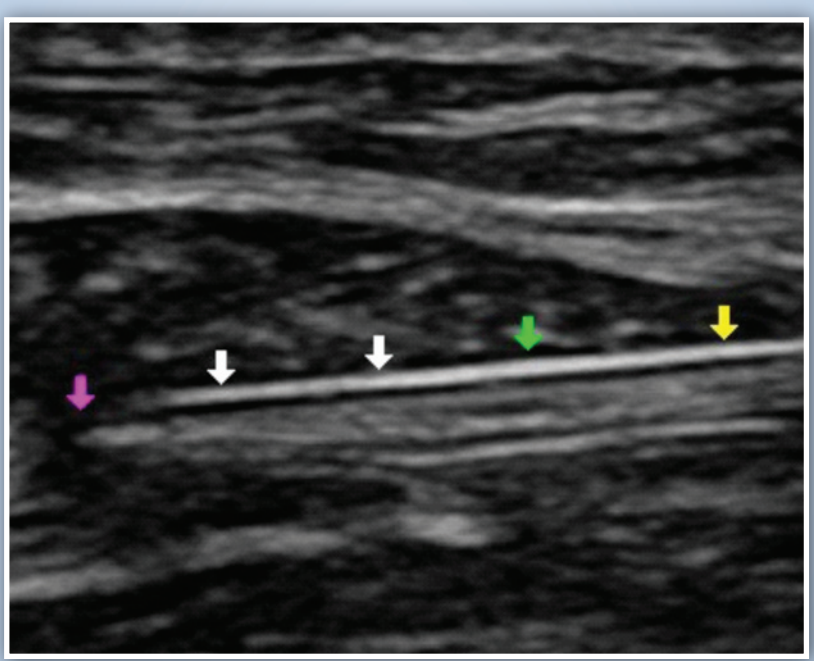

The association for medical ultrasound
aium®
AMERICAN INSTITUTE OF ULTRASOUND IN MEDICINE

© 2014 by the American Institute of Ultrasound in Medicine

The American Institute of Ultrasound in Medicine (AIUM) is a multidisciplinary association dedicated to advancing the safe and effective use of ultrasound in medicine through professional and public education, research, development of parameters, and accreditation. To promote this mission, the AIUM is pleased to publish this *AIUM Practice Parameter for the Performance of Selected Ultrasound-Guided Procedures*. We are indebted to the many volunteers who contributed their time, knowledge, and energy to bringing this document to completion.

Organizations that participated in developing this document, formally approved it, or endorsed it include the American Association of Clinical Endocrinologists (AACE), the American Academy of Otolaryngology—Head and Neck Surgeons (AAO-HNS), the American Academy of Pain Medicine (AAPM), the American Academy of Physical Medicine and Rehabilitation (AAPMR), the American Osteopathic College of Radiology (AOCR), the American Physical Therapy Association (APTA), the American Registry for Diagnostic Medical Sonography (ARDMS), the American Society of Endocrine Physician Assistants (ASEPA), the American Association of Nurse Anesthetists (AANA), and the American Medical Society of Sports Medicine (AMSSM).

The AIUM represents the entire range of clinical and basic science interests in medical diagnostic ultrasound, and, with hundreds of volunteers, the AIUM has promoted the safe and effective use of ultrasound in clinical medicine for more than 50 years. This document and others like it will continue to advance this mission.

These practice parameters of the AIUM are intended to provide the medical ultrasound community with parameters for the performance and recording of high-quality ultrasound-guided procedures. The parameters reflect what the AIUM considers the minimum criteria for the ultrasound-guided procedures addressed in this document but are not intended to establish a legal standard of care. AIUM-accredited practices are expected to follow the parameters with recognition that deviations from these parameters will be necessary in some cases, depending on patient needs and available equipment. Practices are encouraged to go beyond the parameters to provide additional services and information as needed.

The association for medical ultrasound
aium®
AMERICAN INSTITUTE OF ULTRASOUND IN MEDICINE

14750 Sweitzer Ln, Suite 100
Laurel, MD 20707-5906 USA
800-638-5352 • 301-498-4100
www.aium.org

© 2014 by the American Institute of Ultrasound in Medicine

I. Introduction

The clinical aspects of this parameter (Introduction; Supervision, Performance, and Interpretation of the Ultrasound-Guided Procedure; General Specifications for Ultrasound-Guided Procedures; and Specifications for the Individual Procedures) were developed collaboratively. Several sections of this parameter (Qualifications and Responsibilities of Personnel; Written Request for the Ultrasound-Guided Procedure; Documentation; and Quality Control and Improvement, Safety, Infection Control, and Patient Education Concerns) vary between the collaborating organizations and are addressed by each separately.

This parameter has been developed to assist clinicians performing ultrasound-guided procedures. While it is not possible to address every ultrasound-guided procedure, adherence to the following parameters will maximize procedural success and patient safety. While self-evident, all clinicians must also comply with federal and state law in the performance of ultrasound-guided procedures.

II. Qualifications and Responsibilities of Personnel

Individuals who perform ultrasound-guided procedures should be licensed clinicians who are qualified to perform interventional procedures within their scope of practice. (See www.aium.org for AIUM Official Statements, including *Standards and Guidelines for the Accreditation of Ultrasound Practices* and relevant Physician Training Guidelines.)[1–4] They should be familiar with the basic physical principles and limitations of ultrasound imaging as they pertain to diagnostic examinations and interventional procedures; understand ultrasound technology and instrumentation, power output, equipment calibration and safety; and demonstrate familiarity with the anatomic, physiologic, and pathophysiologic characteristics of the anatomic areas in which the procedures will be performed.[5,6] In addition, clinicians performing ultrasound-guided procedures should be capable of correlating complementary diagnostic imaging with ultrasound findings in the context of procedural planning and should be able to determine when alternative modes of image guidance may be appropriate.

Clinicians should provide evidence of the training and competence to perform ultrasound-guided procedures successfully. The training should include the following components[1–13]:

A. Indications and contraindications for ultrasound guidance.

B. Identification of the normal and abnormal ultrasound appearance of tendon, nerve, artery and vein, muscle, bone, and other tissues commonly encountered during ultrasound-guided procedures.

C. Diagnostic scanning for procedural planning, including:
   1. Appropriate transducer selection and image optimization.
   2. Recognition of relevant anatomic variations and unexpected findings.
   3. Interpretation and correlation of ultrasound images with available complementary and diagnostic imaging.

D. Ergonomic considerations for procedural planning.

E. Appropriate needle* or device selection.

F. Ultrasound-guided needle or device tracking using both in-plane and out-of-plane approaches, including the limitations of each technique and methods to optimize needle visualization.

G. Recognition and management of common artifacts relevant to interventional procedures.

H. Recognition and management of procedural complications.

I. Methods of documentation and reporting of ultrasound-guided procedures, including appropriate labeling and recording of images and videos.

**Although "needle" will be used throughout the document, the guidelines also apply to other devices that may be used during ultrasound-guided procedures (eg, biopsy guns and catheters).*

III. Written Request for the Ultrasound-Guided Procedure

The request for an ultrasound-guided procedure should be prepared in compliance with established guidelines and can be in a written or an electronic format.* The request must originate from a physician or other appropriately licensed clinician, or under the physician's or clinician's direction. The requested procedure should be clearly stated and the use of ultrasound guidance specified and justified. In addition, the request should contain sufficient information to document the medical necessity of the procedure and allow for its appropriate performance, including but not limited to known or provisional diagnoses; relevant signs, symptoms, and medical history; and/or the results of complementary diagnostic imaging. Deviation from the requested procedure as reflected on the written or electronic request requires appropriate documentation by the providing clinician.

If the performing clinician is also the referring clinician, the required documentation may be completed through appropriate documentation in the patient's medical record or by generating a formal written or electronic request as dictated by practice-specific requirements.

**Ultrasound-guided anesthesia as part of an operative procedure may not require a written or electronic request.*

IV. Supervision, Performance, and Interpretation of the Ultrasound-Guided Procedure

As subsequently described, a preliminary scan of the target region is completed as part of the procedure and can be performed by the clinician performing the procedure or by a sonographer. If completed by a sonographer, the clinician performing the procedure is responsible for the supervision and interpretation of the preliminary scan in the context of the planned procedure. During the actual procedure, the clinician is responsible for directing the needle to the target region while either the clinician or a sonographer can maintain the transducer over the needle path. The procedural report should be reviewed and signed by the clinician.

V. General Specifications for Ultrasound-Guided Procedures

A. Facility and Personnel

The procedure should be performed in a facility with adequate space and the necessary supplies and personnel for the procedure. Examples of appropriate facilities include a medical office, surgical center, or hospital. Most procedures covered in this document are considered low risk (for exceptions, see section IX. Specifications for Ultrasound-Guided Perineural Procedures and Spinal Pain Procedures; and section X. Specifications for Ultrasound-Guided Fine-Needle Aspiration, Core Biopsy, and Ablative Procedures) and may be performed as point-of-care procedures in an office or surgical center setting. If a higher-risk procedure were to be performed, it would be appropriate to perform the procedure in a location that has the ability to respond to a medical emergency.

B. Equipment

1. Selection of the appropriate ultrasound equipment is critical for procedural success. Clinicians may use either cart-based or portable ultrasound machines to complete a specific procedure, depending on the procedural requirements.
2. Transducer choice is primarily determined by the depth of the target. For superficial structures, a high-frequency (>10-MHz) linear array transducer is appropriate. A small-footprint linear array transducer is often useful to perform procedures in smaller regions with irregular contours, such as the head and neck, wrist-hand, and ankle-foot. For deeper structures, a lower-frequency curved or linear transducer may improve the field of view in the far field.[5,6]
3. Spatial compounding/compound imaging should be used when imaging both superficial and deep structures to enhance the image quality and reduce artifacts, while harmonic imaging may be considered when imaging deep structures. Color or power Doppler imaging assists with the identification of vascular structures to avoid during a procedure and neovessels within tendons, ligaments, and muscle. Detection of low-flow vessels can be enhanced by adjusting Doppler frequencies to detect low-flow states, maintaining the target tissue in a relaxed position, and applying light transducer pressure. Extended field-of-view (ie, panoramic) imaging may be beneficial for preprocedure and postprocedure documentation.
4. All equipment should be available for the planned procedure, including but not limited to sterile gloves, needles, syringes, specialized devices, slides, medications, gauze and dressings, materials for ensuring aseptic technique, and appropriate vials for fluid or tissue collection, as warranted.

C. Specifications for the Performance of Ultrasound-Guided Procedures

1. For all ultrasound-guided procedures, the usual standards for interventional procedures apply (ie, review of prior imaging, appropriate informed consent, site marking as appropriate, use of a local anesthetic as appropriate, and use of aseptic technique). Common procedures performed using ultrasound guidance include but are not limited to injection or aspiration of joints, tendons, or tendon sheaths; aspiration of cysts, fluid collections, and abscesses; peripheral nerve blocks/perineural injections; lavage and aspiration of tendon calcifications; fine-needle aspiration and biopsy; and foreign body retrieval. In general, ultrasound guidance is indicated during these procedures when accuracy is paramount for diagnosis, to ensure therapeutic efficacy or procedural success, or to reduce procedural risk. Details pertaining to selected specific procedural categories are addressed subsequently in this document.

Reviewing the Written Request—Before the procedure, the performing clinician should review the referral request. The written or electronic referral request should clearly document the indication for the ultrasound-guided procedure. Appropriate justification for ultrasound guidance should be included in the referral request or the procedural note. If the performing clinician is also the referring clinician, the required documentation may be completed through appropriate documentation in the patient's medical record or by generating a formal written or electronic request as dictated by practice-specific requirements.

2. Screening for General Contraindications—The appropriate medical history should be reviewed and a focused physical examination performed to ensure that there are no contraindications to performing the procedure. Although there are no known contraindications to the appropriate use of ultrasound guidance to perform a procedure, the following general procedural contraindications apply:
   a. Absolute contraindications:
      i. Known allergy to the injectate.
      ii. Lack of appropriate equipment or skill to complete the procedure.
      iii. Inability of the patient to cooperate with the procedure.
   b. Relative contraindications:
      i. Coagulopathy or anticoagulant/antiplatelet therapy.[12,14,15] Patients with coagulopathy or who are taking anticoagulant or antiplatelet therapies have an increased risk of bleeding complications. Clinicians should be familiar with appropriate national, regional, and practice-specific guidelines. Regardless, bleeding risk can be minimized by using Doppler ultrasound with light transducer pressure to evaluate for regional vasculature before the procedure and by using ultrasound to guide the smallest gauge needle possible toward the target structure (optimally with a single pass) while avoiding adjacent vasculature. After the procedure, the area can be monitored with ultrasound for postprocedure bleeding and hematoma formation.
      ii. Underlying medical condition that may be affected by the injectate (eg, diabetes mellitus that may be affected by corticosteroids).
      iii. Local infection, rash, or skin breakdown.
3. Obtaining Informed Consent—Informed consent should be obtained in accordance with local practice standards and in compliance with applicable state and federal law. The performing clinician should review the planned procedure with the patient and may also consider discussing the use of ultrasound guidance if the patient is unfamiliar with ultrasound-guided procedures. The informed consent should include a discussion of the risks and benefits relevant to the procedure and viable alternative treatments.
4. Ensuring Optimal Room Setup[16]—The patient is placed in a comfortable position to minimize movement. When possible, the patient is placed on the examination table in a dependent position to reduce the risk of a vasovagal episode, particularly when long procedures are anticipated. Ideally, the examination table height should be adjustable, and the height of the table should be adjusted to a position of comfort for the clinician. The target region should be adequately exposed. The clinician should be positioned on the same side as the target region, and the ultrasound machine should be placed such that the clinician can see the target region on the patient and the ultrasound screen with minimal head or neck movement. If possible, the ultrasound transducer should be held with the nondominant hand while the procedure is performed with the dominant hand. However, some clinicians may be equally facile with their dominant

and nondominant hands with respect to transducer and needle manipulation. The tray with the supplies for the procedure should be next to the clinician within easy reach of his or her dominant hand. An assistant may be required to assist the clinician with the ultrasound machine (eg, optimizing the image, saving images, and labeling) and performing the procedure.

5. Performing a Preliminary Scan[5,6,8,12,17]—A preliminary diagnostic scan of the region is completed by the performing clinician or a sonographer with appropriate supervision. This scan is considered part of the ultrasound-guided procedure and serves the primary purpose of procedural planning. If prior soft tissue imaging of the target region has not been performed, the requesting clinician may also request a formal diagnostic scan of the target region before the procedure.

   The primary purpose of the preliminary scan is to optimally identify the target and its relationship to surrounding structures to determine the needle choice (length and gauge), skin entry point, needle trajectory, and tracking technique (in plane versus out of plane). Doppler imaging with light transducer pressure is used to identify regional vasculature, as previously discussed.

   Incidental findings may be encountered during the preliminary scan and may include anatomic variations, associated pathologies, or unassociated pathologies.[8,9] In this setting, the clinician must use appropriate clinical judgment to determine the best course of action: (1) discuss with the requesting clinician before completing the procedure; or (2) complete the requested procedure, with appropriate technical modifications as necessary. The actual requested procedure cannot be changed or amended without appropriate authorization. The clinician should document all significant findings, including any unanticipated findings, in the procedural report and is responsible for appropriate communication to the requesting clinician.

   As part of the preliminary scan, the transducer location may be marked on the skin with an indelible marker. Some clinicians may also choose to mark the anticipated needle entry site. The clinician should also ensure compliance with the facility's policy for adherence to the Joint Commission's *Universal Protocol for Preventing Wrong Site, Wrong Procedure, and Wrong Person Surgery* (www.jointcommission.org).

6. Managing Infection Risk—Ultrasound-guided procedures should be performed in accordance with the facility's infection control guidelines.[18–20] The patient's skin should be cleansed with an antiseptic cleanser. The ultrasound transducer represents a potential source of contamination.[21] Probes should be disinfected between each procedure according to manufacturer recommendations and practice-specific infection control guidelines. The use of sterile drapes, sterile probe covers, and sterile ultrasound gel may provide the best method to reduce the risk of contamination and infection. Alternatives include the use of a sterile glove covering the transducer combined with sterile gel, the use of a sterile condom covering the transducer combined with sterile gel, or the use of a sterile occlusive dressing directly applied to the transducer face combined with sterile gel.[19,22–25] The choice is generally dictated by practice-specific factors (ie, nonsterile sheaths, gel, and gloves may be used if they follow the specific practice or institution guidelines). Clinicians who use the "no-touch" technique place the uncovered transducer over the target region but away from the prepared skin entry site. The needle is passed through the prepared skin region and passes under the transducer within the body. This technique should only be used by experienced clinicians due to the risk of cross-contamination secondary to inadvertent transducer or needle movement. Direct application of non–manufacturer-approved cleaning solutions to the transducer face for disinfection purposes may result in transducer damage and should be avoided. The choice of aseptic technique used during the ultrasound-guided procedure should be documented in the report.

7. Real-time Needle Tracking[5,6,12,13,26]—The transducer should be placed on the patient's skin in the appropriate location, which may be indicated by an indelible marker. The target and relevant anatomic structures are identified. Local anesthesia should be administered in accordance with procedural requirements and practice-specific standards. The needle should be advanced through the skin and guided to the target along the appropriate trajectory using one of the following techniques:
   a. In-plane approach (or long-axis approach; Figure 1):

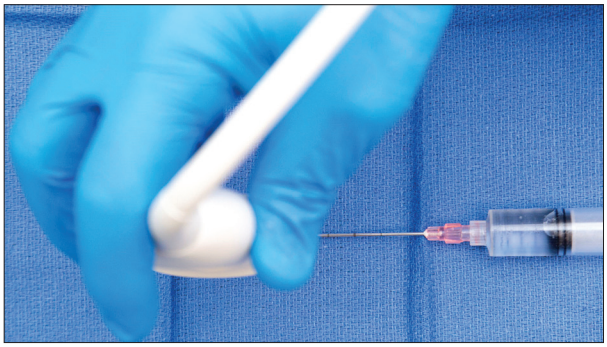

Figure 1A. Demonstration of a "bird's-eye" view from the top of the transducer, looking downward toward the needle. The transducer has been placed directly over the needle and shaft. Thus, the long axis of the transducer is parallel to the long axis of the needle, producing an in-plane sonographic view of the needle.

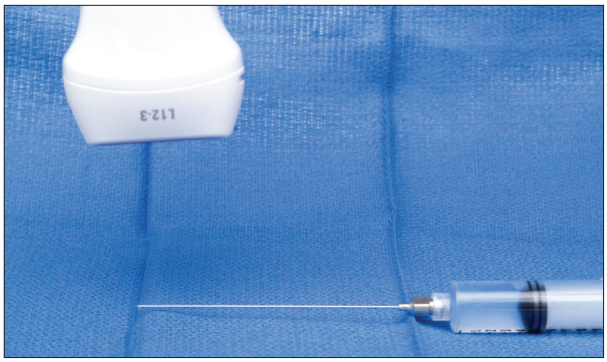

Figure 1B. Correlative view from the side demonstrating the colinearity of the transducer and the needle.

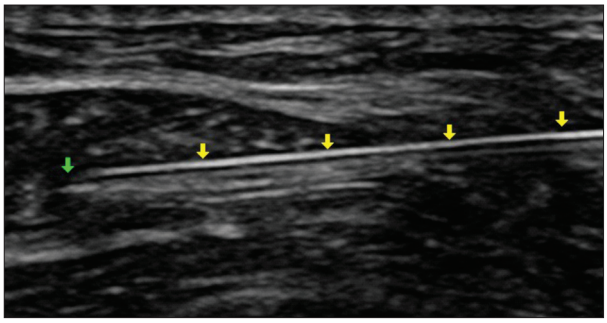

Figure 1C. Ultrasound image generated by the transducer-needle arrangement shown in Figures 1A and 1B. The entire shaft (yellow arrows) and tip (green arrow) can be visualized using the in-plane approach, facilitating optimal control for ultrasound-guided procedures.

The needle is advanced parallel to the long axis of the transducer such that the needle shaft and transducer are colinear. The in-plane technique can be performed freehand or with the assistance of a needle guide. The in-plane technique is often preferred during ultrasound-guided procedures because the needle tip and shaft are visualized throughout the entire procedure.

During the in-plane approach, the conspicuity of the needle is primarily dependent on the angle of the needle with the transducer face. A larger angle (due to a steeper trajectory), renders the needle less conspicuous. The angle effect can be managed in most cases by planning a procedure for a shallower trajectory or using a heel-toe maneuver (discussed subsequently in this document) to bring the transducer face into a more parallel arrangement with the needle. An oblique standoff maneuver may also be used to increase needle-transducer colinearity and therefore needle conspicuity and may be particularly useful in superficial regions with little subcutaneous tissue.

b. Out-of-plane approach (or short-axis approach; Figure 2):

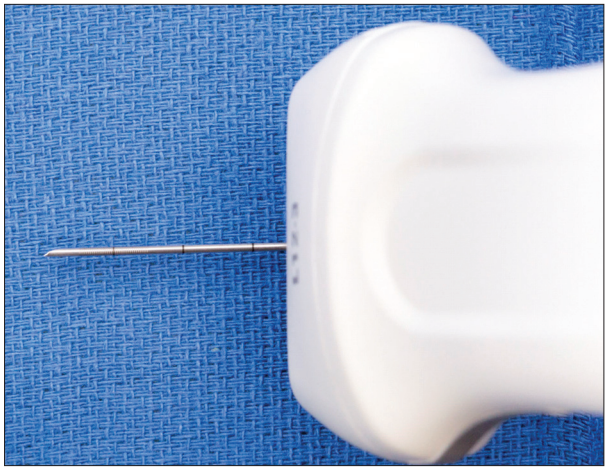

Figure 2A. The needle shaft is perpendicular to the long axis of the transducer. Therefore, the ultrasound beam depicts a cross section of the needle shaft. The ultrasound screen depicts an echogenic dot (Figure 2B), which may represent either the shaft or tip, depending on the relationship between the transducer and the needle. Here, the transducer is over the needle shaft for demonstration purposes. In clinical settings, the clinician would keep the transducer over the needle tip using the techniques described in the text (eg, "walk-down" maneuver).

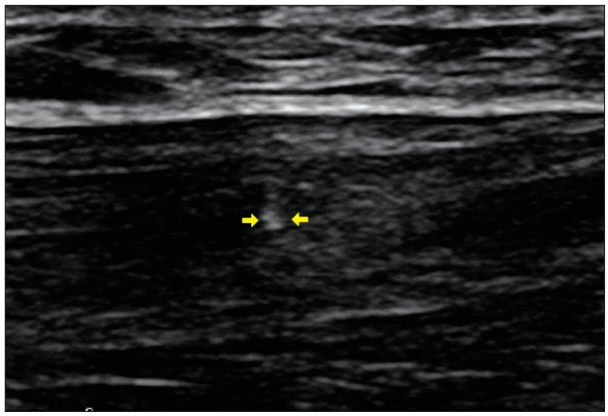

Figure 2B. Correlative ultrasound image demonstrating the appearance of the needle with the transducer-needle arrangement shown in Figure 2A. The ultrasound beam cuts a cross section of the needle, producing an echogenic dot on the screen. The challenge is that, based on this single still image, the clinician cannot tell whether this echogenic dot represents the shaft or the needle tip. Thus, the clinician will advance the needle only to the point at which the echogenic dot first appears on the screen, which represents the initial passage of the needle tip under the transducer. Due to the tendency of the needle to pass beyond the transducer using the out-of-plane approach, confirmatory orthogonal in-plane imaging (Figure 1) should be obtained when possible.

The needle is advanced perpendicular to the long axis of the transducer such that only the needle tip is visualized. Typically, the target is centered on the ultrasound screen, and the needle is passed under the transducer halfway between the left and right ends. The tip of the needle manifests as a hyperechoic "dot" in the center of the screen. As soon as the "dot" is visualized, the clinician stops advancing the needle to keep the tip within the plane of the beam. A common error among less experienced clinicians is to pass the tip beyond the transducer. The first needle pass is typically shallow, and the needle is successively partially withdrawn, angled more steeply, and then advanced toward the target depth: the so-called walk-down maneuver. Some manufacturers have placed a mark halfway across the long axis side of the transducer to facilitate accurate placement of the needle in the center of the transducer for the out-of-plane approach.

The out-of-plane approach is typically used for superficial injections with minimal surrounding soft tissues and is also popular for intravascular needle or catheter placement. It has traditionally been performed using a freehand technique, although applicable needle guides are available. In general, the out-of-plane approach provides less-consistent needle visualization when compared to the in-plane approach.

Although many clinicians prefer one technique over the other, all clinicians performing ultrasound-guided procedures should be competent in both in-plane and out-of-plane needle tracking. Many clinicians switch from one view to another during a procedure to provide orthogonal imaging of the needle and its relationship with the target region as well as surrounding structures of interest. The use of orthogonal imaging is particularly important when tracking toward smaller targets and using the out-of-plane technique.

8. Optimizing Needle Visualization[5,6,11]—While advancing the needle during an ultrasound-guided procedure, the performing clinician should maintain continuous, real-time visualization of the needle and its relationship with the target and surrounding structures. Coordinating transducer and needle positions is integral to maintaining optimal visualization. If the transducer moves or the needle trajectory drifts out from under the transducer, needle visualization will be reduced. The clinician can minimize unwanted transducer risk by firmly anchoring the hand holding the transducer onto the patient. In addition, needle and transducer control may be improved by supporting the elbows or forearms on the table.

   The performing clinician may use one or more of the following techniques to relocate a lost needle or optimize needle visualization during real-time ultrasound guidance:

   a. Transducer manipulation: The following transducer manipulations are useful during the commonly used in-plane approach to locate a needle and optimize visualization:

      i. Translation (Figure 3): The transducer is perpendicular to the skin and is translated (slid or glided) toward the needle until at least a portion of the needle is visualized on the screen.

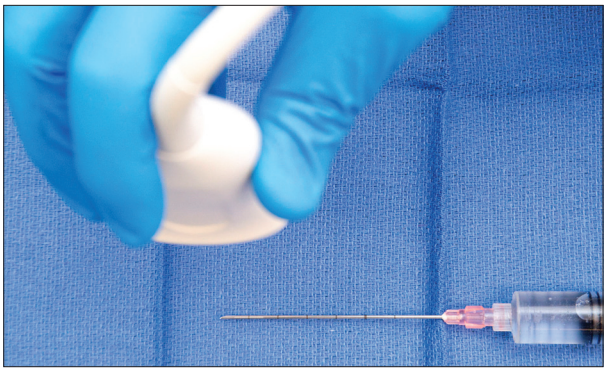

Figure 3A. Demonstration of a "birds-eye" view from the top of the transducer looking downward toward the needle. The transducer is not over the needle; therefore, no part of the needle will be visualized on the screen. The clinician must translate the transducer either toward the top of the image or toward the bottom of the image. A jiggling maneuver (see text for description) is often performed during the translation to produce needle movement that can be detected on the screen. If the direction of translation is correct (in this case, toward the bottom of the image), the amplitude of detected motion will increase until the transducer lies over the needle, at which time the needle will appear on the screen.

Figure 3B. The transducer has been translated and now lies directly over and parallel to the needle shaft.

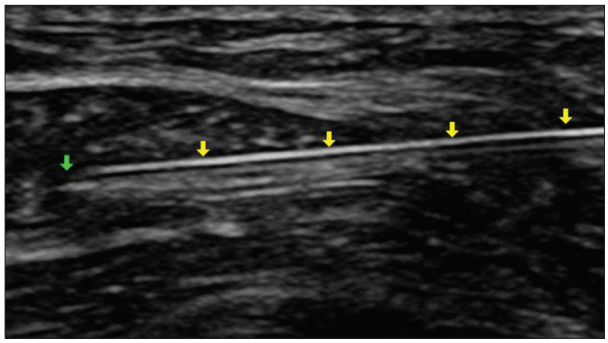

Figure 3C. Correlative ultrasound image demonstrating the appearance of the needle when the transducer is translated over the needle. Note that both the shaft (yellow arrows) and tip (green arrow) of the needle can be visualized as the needle traverses through the tissue.

ii. Rotation (Figure 4): Once the needle is located via translation, if the needle is not colinear with the transducer (ie, only a part of the shaft is visible using the in-plane approach), the transducer is rotated clockwise or counterclockwise to align the long axis of the transducer with the long axis of the needle. During this maneuver, the needle shaft will progressively "stretch" across the screen if the direction of rotation is correct. If the needle shaft "shrinks" on the screen, the direction of rotation is incorrect, and the transducer is then rotated in the opposite direction. Care must be taken to maintain some visualization of the shaft during this maneuver. Less-experienced clinicians will have a tendency to translate the transducer away from the needle as the rotation occurs.

Figure 4A. Demonstration of a "bird's-eye" view from the top of the transducer looking downward toward the needle, similar to Figures 1A, 3A, and 3B. Although the transducer lies over the needle, it is not colinear with the needle. Therefore, the ultrasound image will not show the entire shaft of the needle but only a portion of it. This can lead to an "oblique cross-cut" artifact, in which the oblique view of the needle shaft provides a false impression of where the tip is located (see Figure 4B). The transducer must be rotated to ensure colinearity with the shaft, at which time the tip can be definitively identified. The clinician can rotate the transducer clockwise or counterclockwise. When the correct diagnosis is chosen (in this case, clockwise), the shaft of the needle will elongate on the ultrasound screen, whereas if the incorrect direction is chosen (ie, counterclockwise in this case), the shaft will shorten on the screen.

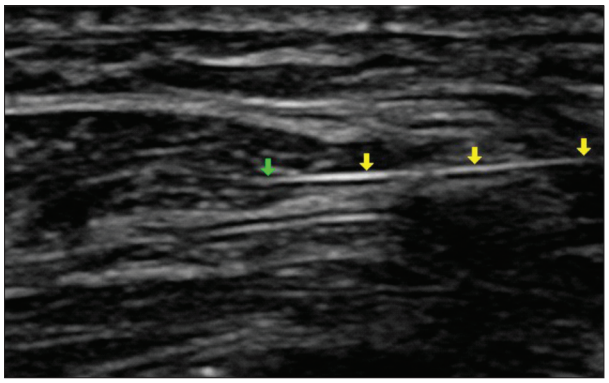

Figure 4B. Correlative ultrasound image of the needle when imaged with the transducer oblique to the needle shaft, as demonstrated in Figure 4A. The shaft is seen on the right side of the screen and is depicted by the yellow arrows. Note that the echogenic superficial border of the stainless steel shaft ends at the green arrow. Without rotating the transducer to ensure maximal colinearity, the clinician may mistake the portion of the shaft identified by the green arrow for the tip of the needle. However, see Figures 4C and 4D.

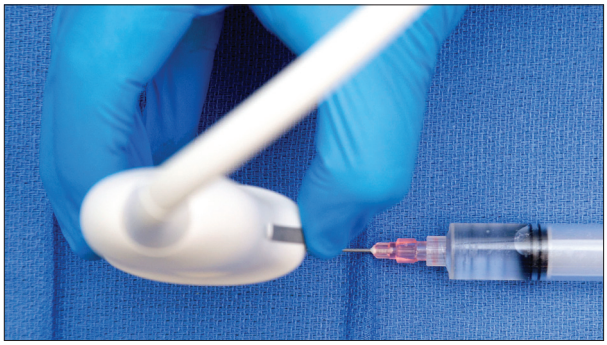

Figure 4C. The transducer has been rotated clockwise, resulting in colinearity with the transducer.

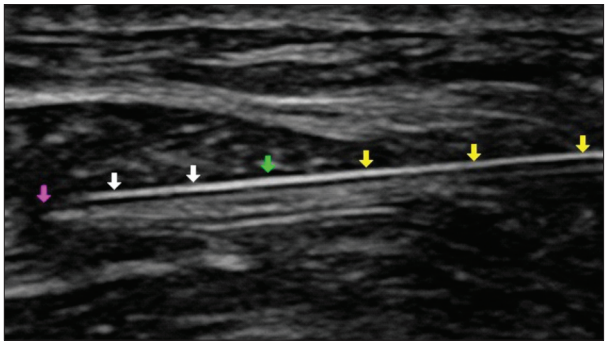

Figure 4D. Correlative ultrasound image for Figure 4C. This is the same needle depicted in Figure 4B. The transducer has been rotated to ensure maximal colinearity with the needle. The region previously thought to be the tip in Figure 4B (green arrow) was not, in fact, the tip but a part of the shaft. With the transducer and needle now colinear, the clinician can appreciate the additional portion of the shaft (white arrows) as well as the true tip (purple arrow), which were not seen in Figure 4B due to an oblique cross-cut artifact.

iii. Heel-toe and oblique standoff (Figure 5):

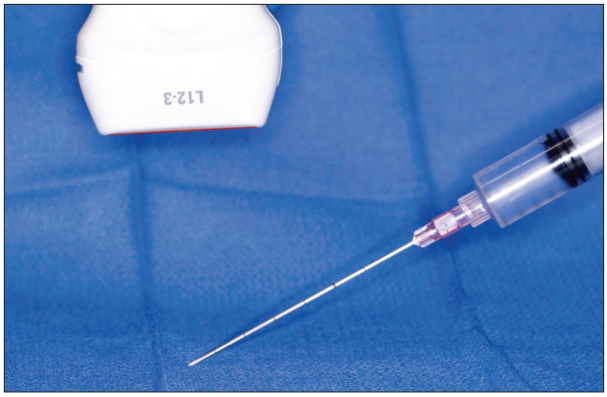

Figure 5A. Demonstration of a side view of a nonparallel arrangement of the transducer and needle. Even though the transducer may be directly over and parallel to the needle as viewed from the surface (ie, "bird's-eye view, as shown in Figures 1A, 3B, and 4C) after translation and rotation, the trajectory of the needle as it passes into the body creates an angulation with the transducer face. As a result, the ultrasound beam does not hit perpendicular to the needle shaft, resulting in reduced visualization (ie, needle anisotropy).

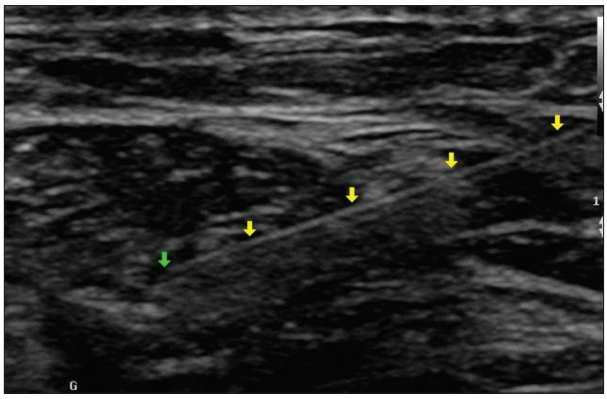

Figure 5B. Correlative ultrasound image demonstrating needle visualization obtained with the transducer-needle arrangement shown in Figure 5A. Note the reduced echogenicity of the needle shaft due to the obliquity of the needle trajectory relative to the transducer face (represented by the top of the screen). Yellow arrows indicate shaft; and green arrow, tip.

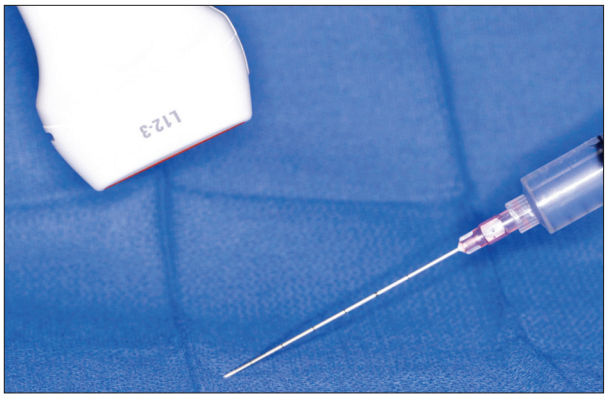

Figure 5C. A heel-toe maneuver is performed to bring the transducer face into a parallel arrangement with the needle shaft (compare with Figure 5A). The ultrasound beam will hit perpendicular to the needle shaft, thus producing optimal visualization.

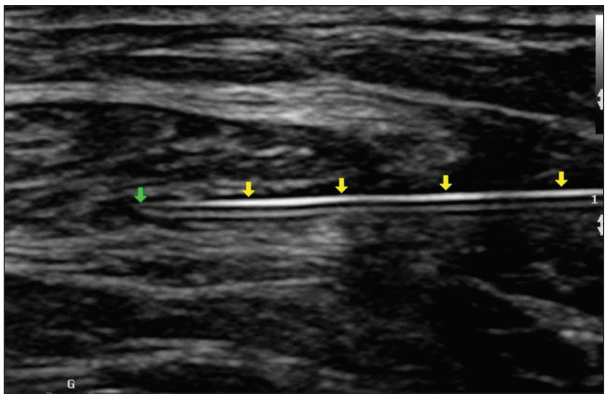

Figure 5D. Correlative ultrasound image demonstrating the appearance of the needle after a heel-toe maneuver to bring the transducer face parallel to the needle shaft. Compared to Figure 5B, the needle shaft is considerably more echogenic, with increased conspicuity, despite the fact that no changes in any ultrasound machine parameters (eg, gain) have been completed. In addition, the tip (green arrow) is now clearly visualized, and one can appreciate the downward-facing bevel.

Once the needle shaft and transducer are colinear, the needle may still be oblique relative to the transducer (ie, the needle shaft and the transducer face are not colinear). This arrangement is more common during procedures directed at deep targets, which require a steep needle trajectory. The obliquity of the needle relative to the transducer face may be reduced by one or two maneuvers. If there is adequate soft tissue, the clinician can perform a heel-toe maneuver by pushing the end of the transducer positioned over the deeper part of the needle into the body (Figure 5). If there is little deformable soft tissue, the clinician may perform an oblique standoff maneuver by elevating the end of the transducer positioned over the shallower part of the needle. In this case, the transducer may lose contact with the skin, in which case the air-filled gap between the transducer and the skin should be filled with sterile gel. The end result of both procedures is to reduce the angle of obliquity of the needle shaft with the transducer face, thus improving needle visualization.

b. Use of needle enhancement features of the ultrasound machine (eg, compound imaging and beam steering).[27]

c. Needle jiggling: The needle is moved back and forth in a low-amplitude, high-velocity motion similar to a sewing machine. The human eye detects this motion relative to the still background on the image. Jiggling is one of the most useful maneuvers during needle tracking, and since the needle tip is not actually advanced during the jiggling maneuver, jiggling can be used as a "beacon" toward which the transducer can be moved to relocate a lost needle (eg, translation, as previously described).

d. Needle rotation: Rotating the needle will result in the bevel alternately facing up and down, thus enabling identification of the needle tip. In many cases, the relatively rough surface of the beveled needle tip will increase the conspicuity of the tip when the bevel is positioned to face in a superficial direction, toward the transducer face and ultrasound beam.

e. Stylet movement: If the needle has a stylet, advancing and withdrawing the stylet within the needle tip can be visualized with ultrasound.

f. Injecting a local anesthetic, sterile saline, or sterile water: Injecting a small amount of a local anesthetic, sterile saline, or sterile water may enhance the ability to image the needle tip by increasing the contrast between the hyperechoic needle tip and surrounding anechoic fluid.[28]

g. Using larger-gauge needles or special echogenic needles may also increase needle conspicuity.[27,29]

9. Documentation—Still images or videos should be used to document the procedure (see section XI. Documentation).

10. Postprocedure Care—After completing the procedure, the needle should be withdrawn from the patient's skin. Postprocedure dressings should be applied as needed and postprocedure instructions reviewed with the patient, as dictated by the specific procedure and practice-specific requirements. The ultrasound equipment should be cleansed with an antiseptic cleanser before use on another patient, as discussed in section 6. Managing Infection Risk.

VI. Specifications for Ultrasound-Guided Joint Aspirations and Injections

A. Introduction

For the purposes of this parameter, ultrasound-guided joint aspirations and injections are defined as procedures in which ultrasound is used to guide a needle into a joint for the purpose of delivering a diagnostic or therapeutic agent or for aspirating fluid. Specifications in this section also apply to periarticular bursas (eg, subacromial bursa in the shoulder and greater trochanteric bursa in the hip).

B. Indications and Contraindications

1. General indications for needle placement into a joint include but are not limited to the following:
   a. Delivery of diagnostic or therapeutic agents into the joint.
   b. Removal of fluid before injection of a diagnostic or therapeutic agent.
   c. Fluid sampling for diagnostic purposes.
   d. Removal of fluid for symptomatic relief.
2. Specific indications for ultrasound-guided needle placement into a joint include but are not limited to the following:[6,12,30–68]
   a. Failed palpation-guided procedure.
   b. Diagnostic aspiration in the setting of clinically absent or minimal effusion.
   c. Diagnostic injection where accurate injectate placement is critical for diagnosis.
   d. Inability to precisely localize the target using palpation or surface landmarks due to:
      i. Body habitus.
      ii. Congenital, postsurgical, or posttraumatic deformity.
      iii. Deep location of the target structure (eg, hip joint).
   e. Therapeutic injection in which therapeutic benefit is predicated on accurate placement.
   f. Relatively high risk of complications that can be mitigated by ultrasound guidance:
      i. Avoidance of inadvertent tendon injection to reduce rupture risk.
      ii. Proximity to neurovascular structures or organs at risk.
      iii. Bleeding risk secondary to anticoagulants or bleeding diathesis (see section V. C. 2. b. Relative Contraindications).
   g. In select patients with significant apprehension about arthrocentesis to ameliorate procedure-related pain and/or anxiety.
3. General procedural contraindications apply as discussed earlier in this document.

C. Considerations for Ultrasound-Guided Joint Aspiration and Injection Procedures

1. General procedural considerations apply as discussed previously in this document.
2. Ultrasound guidance for needle placement into a joint may be performed using a direct or indirect technique.[5,6,56] During the direct technique, the clinician uses real-time ultrasound guidance to place the needle into the joint. In comparison, the indirect technique involves localizing the preferred site of joint entry using ultrasound, marking the skin over the entry site, and advancing the needle to the joint by placing it through the skin mark and along a trajectory to enter the joint. In the indirect technique, the needle is not visualized entering the joint in real time. Although the use of either technique may be appropriate in specific clinical circumstances, the direct technique is preferred due to the ability to visualize the needle in real time throughout the procedure.
3. Clinicians should consider using a small-footprint (hockey stick) transducer in the wrist-hand and ankle-foot region if available. The small footprint will provide procedural versatility and optimize skin contact in these regions of thin soft tissue coverage and bony prominences.
4. Clinicians should physically examine the target joint before aspiration or injection to identify and localize any intra-articular fluid. In some cases, patient positioning may improve the conspicuity of intra-articular fluid as well as dictate its preferential location. Preliminary ultrasound scanning should also seek to localize intra-articular fluid, examining areas where fluid has a predisposition to collect.[69,70] Small quantities of fluid may be targeted for diagnostic aspiration or therapeutic injection, taking advantage of the precise needle placement provided by ultrasound guidance.
5. Multiple approaches are typically available to enter a joint using ultrasound guidance. Clinicians should recognize that many ultrasound-guided joint aspirations and injections do not use the same approaches as traditional non–image-guided techniques. The choice of joint entry site for an ultrasound-guided procedure is situation specific and depends on patient position and regional anatomy, localization of fluid (if any), the proximity of neurovascular structures, and clinician preference.[34,37,42,44,45,71] Whereas ultrasound-guided joint injections may be performed with smaller-gauge needles, larger-gauge needles are recommended for aspiration (eg, 20 gauge or larger).
6. After intra-articular needle positioning, the clinician may consider a "test injection" with a small amount of sterile normal saline, sterile water, or a local anesthetic to confirm intra-articular placement and free injectate flow. A test injection may be particularly useful in the presence of copious intra-articular debris or synovitis.
7. During joint injection, fluid should flow freely from the needle tip into the joint space. In the absence of free flow, the needle should be repositioned. Depending on the amount of fluid injected and the size of the joint space, the clinician may document a sonographic arthrogram by visualizing distention of the joint recesses sonographically during or after the injection.
8. During joint aspiration, the clinician should reposition the needle into the fluid using ultrasound guidance to optimize the yield of the aspiration and avoid needle clogging with synovial tissue or joint debris. When infection is suspected, the needle path should be chosen with awareness of the potential for contamination of the tissues adjacent to the joint due to bacterial leakage from the joint or cross-contamination from the needle during withdrawal. If there is no intra-articular fluid as determined by ultrasound and infection is suspected, the clinician may consider joint lavage with sterile

nonbacteriostatic normal saline or sterile water to facilitate aspiration, with the recognition that lavage will dilute the concentration of any intra-articular bacteria or cells. However, in this case, a Gram stain and cultures may still be valid. Nonbacteriostatic saline would not be needed if there was no suspicion of infection, and the procedure was being performed for other indications (eg, crystal aspiration).

9. Although not specifically covered in this section, ultrasound-guided synovial biopsy can be performed using similar techniques and principles but targeting sonographically visualized intra-articular synovial tissue.

10. After completing the procedure, the needle should be withdrawn from the patient's skin. Postprocedure dressings should be applied based on the procedure and postprocedure instructions reviewed with the patient (see also section V. C. 10. Postprocedure Care).

VII. Specifications for Ultrasound-Guided Tendon, Ligament, and Muscle Procedures

A. Introduction

For the purposes of this parameter, ultrasound-guided tendon, ligament, and muscle procedures are defined as procedures in which real-time ultrasound visualization is used to guide a needle or similar device into a tendon sheath, tendon, ligament, or muscle for the purposes of delivering a diagnostic or therapeutic agent or performing a therapeutic intervention such as tenotomy or removal of calcium deposits. These specifications also apply to fascia (eg, plantar fasciopathy).

B. Indications and Contraindications

1. General indications for interventional procedures on tendons, ligaments, and muscles include but are not limited to the following:
   a. Tendinopathy (tendinosis and partial-thickness tears).
   b. Enthesopathy.
   c. Tenosynovitis. (In the case of stenosing tenosynovitis, an ultrasound-guided A1 pulley release can be performed if indicated.)
   d. Tendon snapping, subluxation, or dislocation (eg, internal coxa saltans due to the iliopsoas tendon).
   e. Ligament sprains.
   f. Entrapment of a structure by a ligament (eg, transverse carpal ligament compressing the median nerve at the wrist).
   g. Muscle contusions.
   h. Muscle trigger points and tender points.
2. Specific indications for ultrasound guidance for interventional procedures on tendons, ligaments, and muscles include but are not limited to the following:[6,12,50,68,72–102]
   a. Failed palpation-guided procedure.
   b. Diagnostic injection where accurate injectate placement is critical for diagnosis.

c. Inability to precisely localize the target using palpation or surface landmarks due to:
   i. Body habitus.
   ii. Congenital, postsurgical, or posttraumatic deformity.
   iii. Deep location of the target structure (eg, flexor hallucis longus tendon at the posterior process of the talus).

d. Therapeutic injection in which therapeutic benefit is predicated on accurate placement.

e. Relatively high risk of complications that can be reduced by ultrasound guidance:
   i. Avoidance of inadvertent tendon injection to reduce rupture risk.
   ii. Proximity to neurovascular structures or organs at risk.
   iii. Bleeding risk secondary to anticoagulants or bleeding diathesis (see section V. C. 2. b. Relative Contraindications).

f. In select patients with significant apprehension about injections to ameliorate procedure-related pain and/or anxiety.

3. General contraindications apply as discussed earlier in this document.

C. Considerations for Ultrasound-Guided Tendon, Ligament, and Muscle Procedures

1. General procedural considerations apply as discussed previously in this document.
2. Clinicians should consider using a small-footprint (hockey stick) transducer in the wrist-hand and ankle-foot region if one is available. The small footprint will provide procedural versatility and optimize skin contact in these regions of thin soft tissue coverage and bony prominences.
3. Tendons should be positioned in a moderately relaxed position, particularly when Doppler flow will be used during the procedure. Loose tendons will introduce anisotropy, whereas tight tendons will artifactually demonstrate reduced neovascularization and increase resistance to needle passage and injection.
4. After the needle tip has been guided into the target or target area as described previously in this document, one of the following procedures can be performed:

   a. Injection:
      i. For the purposes of injection, the needle can be placed adjacent to the tendon (or within its sheath, as appropriate), into the tendon, adjacent to or into a ligament or fascia, or into a muscle either parallel or perpendicular to the long axis of the target structure (ie, while visualizing the structure in its short or long axis).[77, 80–96,98–104]
      ii. After a negative aspirate for blood, a therapeutic or diagnostic substance can be delivered into the target region under direct ultrasound visualization.
      iii. As indicated, a "test injection" with a local anesthetic, sterile normal saline, or sterile water may be performed before delivery of the injectate to confirm accurate needle placement and free flow. If free flow away from the needle tip is not visualized, the needle should be repositioned.
      iv. The clinician should visualize the expected distribution of the injectate using real-time ultrasound guidance.
      v. Intratendinous and intraligamentous cortisone injection should be avoided due to the risk of tendon rupture.

b. Aspiration:

i. Fluid can be aspirated from the target area for diagnostic or therapeutic purposes. Several approaches are typically available to place a needle into a fluid collection using ultrasound guidance while avoiding neurovascular structures.

ii. In the setting of suspected infection, fluid should be sent for analysis and culture because the ultrasound appearance of fluid is an unreliable indicator of infection. Similarly, the viscosity of the fluid cannot be predicted by its ultrasound appearance, and many fluid collections are more viscous than anticipated. Use of larger-gauge needles and lavage with sterile normal saline, sterile water, or a local anesthetic can be performed to reduce viscosity and facilitate aspiration. Although lavage may be useful for therapeutic decompression, lavage should be used with caution in suspected cases of infection, as the lavage fluid will dilute bacteria and cells and may inhibit bacterial culture.

iii. The clinician should reposition the needle during the procedure to avoid needle clog and optimize fluid aspiration. In the setting of ganglia or other septated fluid collections, the clinician can guide the needle into additional compartments to optimize the yield.

c. Tenotomy, fenestration, calcific deposit barbotage, and trigger point needling:

i. The clinician can use real-time ultrasound guidance to perform several therapeutic procedures with standard stainless steel needles or specialized devices, including tenotomy, fenestration, disruption and aspiration of intratendinous calcific deposits (barbotage), trigger point needling, and "tendon scraping."

ii. "Tenotomy" can be performed for chronic tendinopathy, plantar fasciopathy, and ligament sprains with the goal of disrupting degenerative tissue and facilitating healing. Needle tenotomy is performed by repetitively fenestrating the pathologic region under real-time ultrasound guidance. The needle is typically oriented parallel to the tissue fibers but can be oriented perpendicular to the fibers.[77,94,105–108] In either case, one or more needle passes are completed through each affected region. Needle size may vary, but larger-gauge needles (eg, 18 gauge) are often used. Orthogonal short- and long-axis imaging of the target tissue is used to control the needle position and ensure that all regions are treated. Tenotomy may also be performed with specialized devices that specifically cut, fragment, and in some cases remove tissue.[109,110] General technical considerations are similar to those for needle tenotomy with the addition of device-specific considerations. Needle fenestration can also be used to treat entrapments such as carpal tunnel syndrome and stenosing tenosynovitis. The clinician repetitively fenestrates the entrapping structure (eg, A1 pulley in stenosing tenosynovitis) to reduce tension.[72,111–113] Similar to tenotomy, "fenestration" may also be completed with specialized tools or devices that cut or transect the restrictive tissues as opposed to fenestration.[74,75,114–118]

d. Ultrasound-guided lavage and aspiration (barbotage) of calcific tendinosis is a well-established clinical procedure providing good or excellent outcomes in the

majority of appropriately treated patients.[119–124] After local anesthesia, one or two needles are placed under direct ultrasound guidance into the calcific deposit, followed by lavage with sterile water or sterile saline mixed with a local anesthetic. After barbotage, an ultrasound-guided subacromial bursa injection is typically performed.

e. There are numerous techniques for treating myofascial pain with dry needling or injection, and ultrasound can be used to guide a needle into the trigger point.[125,126]

f. "Tendon scraping" is typically performed with a large-gauge needle (18 gauge or larger) or in some cases a small scalpel blade or similar instrument. The needle or blade is positioned outside the tendon, adjacent and superficial to the paratenon. (The procedure is typically performed for nonsynovial tendons affected by chronic tendinopathy.) The needle/blade is then moved back and forth along the paratenon in a scraping motion to disrupt neovessels and pain-mediating nerve fibers typically located in the peritendinous tissue.[127]

g. After completing the procedure, the needle should be withdrawn from the patient's skin. Postprocedure dressings should be applied based on the procedure and postprocedure instructions reviewed with the patient (see also section V. C. 10. Postprocedure Care).

VIII. Specifications for Ultrasound-Guided Fluid Aspirations[12,68,128,129]

A. Introduction

For the purposes of this parameter, ultrasound-guided fluid aspiration procedures are defined as procedures in which real-time ultrasound visualization is used to guide a needle or catheter into a fluid collection (eg, cyst, seroma, ganglion, or abscess) for diagnostic or therapeutic aspiration. Diagnostic and therapeutic joint aspirations are reviewed in section VI. Specifications for Ultrasound-Guided Joint Aspirations and Injections, and some aspects of ultrasound-guided fluid drainage are covered in sections VI. Specifications for Ultrasound-Guided Joint Aspirations and Injections, and VII. Specifications for Ultrasound-Guided Tendon, Ligament, and Muscle Procedures.

B. Indications and Contraindications

1. General indications for placing a needle or catheter into a fluid collection include but are not limited to the following:

   a. Diagnostic aspiration for fluid analysis to exclude infection, metallosis, crystal disease, and other etiologies of abnormal fluid collections.

   b. Therapeutic aspiration for symptomatic relief or to facilitate resolution of the fluid collection.

   c. Installation of a catheter for therapeutic drainage of a fluid collection.

   d. Installation of therapeutic agents such as corticosteroids and sclerosing agents.

2. Specific indications for ultrasound guidance to place a needle or catheter into a fluid collection include but are not limited to the following:
   a. Failed non–ultrasound-guided procedure, including recurrent fluid collection following a palpation-guided procedure.
   b. Non–clinically palpable fluid collection seen on ultrasound, computed tomography, or magnetic resonance imaging.
   c. Inability to precisely localize the target using palpation or surface landmarks due to:
      i. Body habitus.
      ii. Congenital, postsurgical, or posttraumatic deformity.
      iii. Deep location of target structure.
   d. Relatively high risk of complications that can be reduced by ultrasound guidance:
      i. Proximity to neurovascular structures or organs at risk.
      ii. Bleeding risk secondary to anticoagulants or bleeding diathesis (see section V. C. 2. b. Relative Contraindications).
   e. In select patients with significant apprehension about interventional procedures to ameliorate procedure-related pain and/or anxiety.
3. General contraindications apply as discussed earlier in this document.

C. Considerations for Ultrasound-Guided Fluid Aspirations[6]
1. General procedural considerations apply as discussed previously in this document.
2. Fluid can be aspirated from the target area for diagnostic or therapeutic purposes. Several approaches are typically available to place a needle into a fluid collection using ultrasound guidance while avoiding neurovascular structures. The choice of approach is dictated by patient-specific factors. In general, the shortest trajectory to the fluid collection is chosen while avoiding "at-risk" structures such as internal organs, nerves, and vessels.[50]
3. Needle size should be determined based on procedural specifics. Larger-gauge needles should be used for complex fluid collections and in cases where fluid is anticipated to be viscous. The viscosity of the fluid cannot be predicted by its ultrasound appearance, and many fluid collections are more viscous than anticipated. Use of larger-gauge needles and lavage with sterile normal saline, sterile water, or a local anesthetic can be performed to reduce viscosity and facilitate aspiration. Although lavage may be useful for therapeutic decompression, lavage should be used with caution in suspected cases of infection, as the lavage fluid will dilute bacteria and cells and may inhibit bacterial culture, and if performed too vigorously in a large abscess, the maneuver could potentially induce sepsis.
4. When attempting to aspirate small ganglia, a short beveled needle may be considered to allow the entire bevel to be placed into the cyst.
5. Real-time ultrasound guidance can be used to redirect the needle or catheter within a loculated fluid collection to optimize the yield. Needles can also be used to penetrate septa and adhesions, as well as fenestrate the walls of ganglion cysts to facilitate autodecompression.

6. In the setting of suspected infection (ie, abscess), the performing clinician should choose a needle path that avoids or minimizes the risk of contamination of adjacent tissues or tissue compartments. If there is any question of infection, fluid should be sent for analysis and/or culture because the ultrasound appearance of fluid is an unreliable indicator of infection.
7. After completing the procedure, the needle or catheter should be withdrawn from the patient's skin and dressings applied based on the procedure. Postprocedure instructions should be reviewed with the patient (see also section V. C. 10. Postprocedure Care).
8. Any drains left in place should be managed in accordance with facility guidelines.

IX. Specifications for Ultrasound-Guided Perineural and Spinal Pain Procedures

A. Introduction

For the purposes of this parameter, ultrasound-guided perineural procedures are defined as procedures in which real-time ultrasound visualization is used to guide a needle, catheter, or similar device adjacent to neurologic structures for the purpose of delivering a diagnostic or therapeutic agent or performing a therapeutic intervention (eg, placement of a peripheral nerve stimulator).

B. Indications and Contraindications

1. General indications for interventional procedures adjacent to central or peripheral neurologic structures include but are not limited to the following:
   a. Anesthesia for surgical procedures.
   b. Analgesia after surgical procedures.
   c. Diagnosis and treatment of neurologic and musculoskeletal pain syndromes.
      i. Injections.
      ii. Perineural catheter placement.
2. Given the goal of placing a needle, catheter, or similar device directly adjacent to sensitive neurologic structures, image guidance is generally indicated when performing perineural procedures both centrally and peripherally. Whereas ultrasound guidance is optimally suited for image guidance in the periphery, the indications for ultrasound guidance with respect to central neurologic procedures are less well established.[130]
3. General contraindications apply as discussed earlier in this document.

C. Considerations for Ultrasound-Guided Perineural Procedures[130,131]

1. General procedural considerations apply as discussed previously in this document.
2. The clinician must demonstrate both clinical and technical expertise to safely perform ultrasound-guided perineural procedures, including needle tracking using both in-plane and out-of-plane techniques. Because of the systemic local anesthetic toxicity and associated complications from the injection of local anesthetics, regional anesthesia should be performed in a monitored setting with appropriate supervision and cardiopulmonary resuscitative equipment. Certain perineural injections may need to be performed in a monitored setting, especially spinal nerve blocks or those requiring large amounts of local anesthetics, such as proximal nerve blocks used for anesthesia of an entire limb. For those particular procedures, appropriate monitors should be applied and at a minimum include noninvasive blood pressure, continuous electrocardiography, and pulse oximetry. Monitoring is not required during the performance of injections such as carpal tunnel injections. Supplemental oxygen is advised when sedating patients.
3. The clinician should demonstrate expertise in identification of nerves, including differentiation of nerves from surrounding tissues, recognition of pathologic nerves and anatomic variations, and incidental findings.[9,10,17]
4. A shallow needle trajectory is used to direct the needle to the perineural region to minimize the risk of direct nerve penetration.
5. Use of both in-plane and out-of-plane needle tracking is necessary to optimize needle guidance accuracy.
6. During the injection, the spread of injectate should be monitored. All traditional safety precautions must be used when physically injecting a local anesthetic.[132] Failure to visualize the local anesthetic injection may result in an intravascular or intraneural injection.
7. If the patient is sedated or awake for the peripheral nerve block, neuropathic pain on injection can be appreciated. If neuropathic pain is encountered, the injection must stop and the needle repositioned.
8. In the perioperative setting, due to the toxicity and associated complications from the injection of local anesthetics, regional anesthesia should be performed in a monitored setting with appropriate supervision and cardiopulmonary resuscitative equipment. Appropriate monitors should be applied and at a minimum include noninvasive blood pressure, continuous electrocardiography, and pulse oximetry. Supplemental oxygen is advised when sedating patients.
   a. Perineural catheter placement:
      i. Perineural catheters are most commonly placed when prolonged analgesia is necessary, such as for a total knee replacement or triple ankle arthrodesis. Continuous perineural infusion of a local anesthetic and adjuvants may also be used to facilitate physical therapy and rehabilitation in various chronic pain syndromes.
      ii. When placing a perineural catheter, it is imperative that the highest level of sterility be applied to avoid infection. The area is widely prepared with an antiseptic solution and draped in a sterile manner. The clinician should wear a cap, mask, and sterile gloves, and use of a sterile gown is advisable. The probe is appropriately disinfected before the procedure, as previously discussed (see section V. C. 6. Managing Infection Risk). Use of a sterile ultrasound transducer cover and sterile ultrasound gel is highly recommended for these procedures.

iii. Perineural catheters may be placed by using an in-plane or out-of-plane approach. At times, the precise location of the catheter tip is not evident, and the clinician must confirm that intravascular placement of the catheter has not occurred. Testing for intravascular catheter placement includes attempting to aspirate blood before injecting and administering a test solution such as 3 to 5 mL of 1.5% lidocaine with 1:200,000 epinephrine. If the catheter is intravascular, an unusual increase in the heart rate of 10 to 20 beats per minute may occur. Finally, the local anesthetic of choice (eg, bupivacaine or ropivacaine) is administered slowly with frequent aspiration (every 3–5 mL) while assessing for symptoms of systemic local anesthetic toxicity. Finally, the catheter is fixated with a sterile adhesive dressing.

b. After completing the procedure, the needle should be withdrawn from the patient's skin. Postprocedure dressings should be applied based on the procedure. Any drains left in place should be managed in accordance with facility guidelines. Postprocedure instructions should be reviewed with the patient (see also section V. C. 10. Postprocedure Care).

D. Considerations for Ultrasound-Guided Spinal Pain Medicine Procedures[133,134]

1. General procedural considerations apply as discussed previously in this document.
2. Ultrasound-guided pain procedures are typically performed in a specialized procedure room by a clinician treating acute and chronic pain.
3. Ultrasound provides good visualization of bony surfaces and thus is useful to provide guidance for various superficial axial or spine injections, such as medial-branch blocks, intra-articular facet injections, nerve root blocks, and sacroiliac joint injections.
4. Although ultrasound-guided neuroaxial blocks may provide some advantages when compared to traditional landmark-based approaches in regional and obstetric anesthesia, the role of ultrasound guidance to perform spinal blocks traditionally performed using fluoroscopic or computed tomographic guidance is less well defined and is therefore beyond the scope of this document.[135,136]

X. Specifications for Ultrasound-Guided Fine-Needle Aspiration, Core Biopsy, and Ablative Procedures[68,137]

A. Introduction

For the purposes of this parameter, ultrasound-guided "fine needle aspiration, core biopsy, and ablative procedures" refers to the use of ultrasound guidance to obtain samples for material analysis, instill agents into spaces or tissues, or install devices into tissues for the purpose of performing an ablative procedure. Most of this point-of-care sampling will be performed for lesions of the head, neck, and breast, as well as superficial soft tissue masses in other parts of the body. Deep-organ biopsy (eg, liver and pancreas) is typically performed in the hospital or appropriate controlled setting under the supervision of a radiologist and is beyond the scope of this document. Similarly, this parameter does not apply to ultrasound-guided biopsy of the prostate or the various currently available gynecologic sampling techniques.

B. Indications and Contraindications

1. Image guidance is generally indicated for percutaneous soft tissue sampling or ablative procedures to ensure accurate needle or device placement, avoid unnecessary contamination of adjacent tissue compartments, optimize the diagnostic yield, accurately deliver ablative/therapeutic agents, and/or minimize complications. Specific indications for ultrasound guidance include but are not limited to the following:
   a. Fine needle aspiration for sampling accessible thyroid and parathyroid nodules, lymph nodes, cysts, salivary glands, congenital cervical mass lesions, muscle, soft tissue masses, and abscesses of the head and neck region. Samples may be submitted for cytology, flow cytometry, hormone analysis (thyroglobulin, calcitonin, parathormone, and amylase), genetic and molecular markers, and cultures of infectious lesions.
   b. Core biopsy of lymph nodes suspicious for lymphoma, aggressive thyroid lesions such as cytologically suggested anaplastic or poorly differentiated malignancy, lesions with previous indeterminate, inadequate, or unsatisfactory cytology, and rare salivary gland malignancy where an understanding of precise histology is critical to surgical decisions regarding the facial nerve. Fine-needle aspiration for cytology, often with flow cytometry when lymphoma is suspected, should precede consideration of core biopsy. When results are equivocal and Hodgkin lymphoma is suspected, a tissue sample is required with core biopsy as a first step before open biopsy.
   c. Fine-needle aspiration of breast lesions. However, most breast surgeons and radiologists prefer to perform core breast sampling as an initial assessment rather than fine-needle aspiration with cytology.
   d. Percutaneous ethanol injection of thyroid cysts, selected metastatic papillary carcinoma in lymph nodes, and specific hyperparathyroid conditions. Except for thyroid cysts, which have a very low complication rate, ethanol injections for other conditions are highly specialized and should be reserved for centers with specific interest and experience in these treatments.
   e. Installation of sclerosing agents to treat macrocystic lymphangiomas and cystic hygromas.
2. General contraindications apply as discussed earlier in this document.
3. There are no specific contraindications to ultrasound-guided fine-needle aspiration or core biopsy, with only a few exceptions:
   a. If important nerves such as the facial nerve or brachial plexus are at definite risk, ultrasound-guided fine-needle aspiration may be avoided in favor of open sampling.
   b. In the postoperative neck, a traumatic neuroma may be identified as a hypoechoic mass lesion in contiguity with its associated nerve. Deep palpation of the mass with the transducer may produce focal pain (ie, sonopalpation), which may radiate along the nerve pathway. The posttraumatic neuroma should not be sampled.
   c. Relative contraindications to large-bore needle aspirates and core needle biopsy are anticoagulation, intervening loops of bowel, an overlying large artery, an ovarian mass, and a renal mass.

C. Considerations for Ultrasound-Guided Fine-Needle Aspiration, Core Biopsy, and Ablative Procedures

1. In addition to the general qualifications for performance of ultrasound-guided procedures discussed previously in this document, clinicians performing ultrasound-guided fine-needle aspiration, core biopsy, and ablative procedures may require competency in appropriate core sample preparation and slide preparation as clinical practice dictates. This includes efficient placement of slides into solutions and other preparation techniques to avoid air-drying artifacts.
2. If soft tissue imaging of the target region has not been completed before the request for biopsy or treatment, a diagnostic ultrasound examination should be performed at the time of the procedure. The referring clinician should be notified of any unanticipated findings, as discussed earlier in this document. If a previous ultrasound examination has been performed elsewhere, the diagnostic procedure should be repeated and saved before guided biopsy to make certain that there is symmetry of thought. Even if the same clinician is performing the sampling procedure after a time interval, it is important to repeat the critical elements of the ultrasound to plan a best course of action.
3. After completing the procedure, the needle should be withdrawn from the patient's skin, and dressings should be applied based on the procedure. Postprocedure instructions should be reviewed with the patient (see also section V. C. 10. Postprocedure Care).

XI. Documentation[138]

Each organization will address this section in its document. AIUM language is as follows:

A. Adequate documentation is essential for high-quality patient care, should be performed in accordance with the *AIUM Practice Parameter for Documentation of an Ultrasound Examination*, and should be permanently documented in the patient's medical record. Retention of the ultrasound examination should be consistent both with clinical needs and with relevant legal and local health care facility requirements. The procedure documentation should include the following:

1. Patient identification.
2. Facility identification.
3. Procedure date.
4. Requested procedure, including side of body. Documentation of changes to the requested procedure should be included as appropriate.
5. Indication for the procedure.
6. Justification for ultrasound guidance.
7. Description of the target and relevant associated structures, both normal and abnormal.
8. Description of the use of ultrasound to localize the target and the essential elements of the procedure, including transducer position, approach to the target, and method of needle tracking (in plane or out of plane). Deviations from standard techniques are described and justified.
9. The type and amount of medication, if used.
10. Needle/device type and gauge.
11. Specimens removed, if any, as well as their disposition.

12. Preprocedure, intraprocedure, and postprocedure still image(s) or videos:
    a. Images should be labeled with the patient identification, facility identification, procedure date, and side (right or left) of the procedure site.
    b. Inclusion of at least one image demonstrating the needle or device placed into the target region is required unless the indirect technique is used (see section VI. Specifications for Ultrasound-Guided Joint Aspirations and Injections).
    c. All images should be permanently archived and easily retrievable.
    d. Variations from normal size or morphology should be recorded and accompanied by measurements.

XII. Quality Control and Improvement, Safety, Infection Control, and Patient Education Concerns

Each organization will address this section in its document. AIUM language is as follows:

A. Policies and procedures related to quality control and improvement, patient education, infection control, and safety should be developed and implemented in accordance with the *AIUM Standards and Guidelines for the Accreditation of Ultrasound Practices*. Infection control issues have been addressed elsewhere in this document. Ultrasound transducer cleaning, disinfection, and sterilization should be performed in accordance with the *AIUM Guidelines for Cleaning and Preparing External- and Internal-Use Ultrasound Probes Between Patients*.

B. Equipment performance monitoring should be in accordance with the *AIUM Standards and Guidelines for the Accreditation of Ultrasound Practices*. This should include following the ultrasound manufacturer's equipment care and maintenance recommendations and having the equipment checked at least on an annual basis.

C. Practices performing ultrasound-guided procedures should have policies and procedures in place to ensure the safety of the patient and practice personnel during the procedure. These include but are not limited to the following:
    1. Policies on Prevention of Infectious Diseases—The practice must have procedures and policies for the protection of patients and practice personnel from the transmission of infectious diseases as well as the cleaning and disinfection of ultrasound equipment and transducers.
    2. Policies and Procedures Safeguarding Patients, Practice Personnel, and Equipment—The facility should have a formal policy for adherence to the Joint Commission's *Universal Protocol for Preventing Wrong Site, Wrong Procedure, and Wrong Person Surgery* (www.jointcommission.org).
    3. Policies and Procedures for Adequate Labeling of Specimens—The practice must clearly define the personnel responsible and the steps required to hand off each specimen.
    4. ALARA Principle—Personnel must be familiar with and show evidence of practicing the ALARA (as low as reasonably achievable) principle with use of ultrasound.

D. Incident Reporting—A policy/procedure must exist for responding to and reporting any accidents or complications that occur in the facility. This policy/procedure should comply with any applicable reporting requirements under state and federal law.

E. Patient Confidentiality—All practice personnel must adhere to Health Insurance Portability and Accountability Act (HIPAA) regulations, state privacy laws, and professional ethics and behavior to ensure patient confidentiality

F. Quality Assurance—The practice must show ongoing monitoring of the clinical practice's personnel performance, including all clinicians and sonographers.

XIII. ALARA Principle

The potential benefits and risks of each examination should be considered. The ALARA principle should be observed when adjusting controls that affect the acoustic output and by considering transducer dwell times. Further details on ALARA may be found in the AIUM publication *Medical Ultrasound Safety, Third Edition*.

Acknowledgments

Principal Drafter:

Jay Smith, MD

Vice Chair, Physical Medicine and Rehabilitation

Professor of Physical Medicine and Rehabilitation

Mayo Clinic School of Medicine

Mayo Clinic

Rochester, Minnesota

Work Group Leaders:

Jonathan T. Finnoff, DO

Associate Professor of Physical Medicine and Rehabilitation

Mayo Clinic School of Medicine

Mayo Clinic

Rochester, Minnesota

John FitzGerald, MD, PhD

Associate Clinical Professor of Rheumatology

Interim Chief of Rheumatology

UCLA Rheumatology

Los Angeles, California

Gerald Minkowitz, MD

Medical Director

Minkowitz Pathology, PC

Brooklyn, New York

Samer N. Narouze, MD, PhD

Clinical Professor of Anesthesiology and Pain Management, Ohio University

Clinical Professor of Neurological Surgery, Ohio State University

Chairman, Center for Pain Medicine

Western Reserve Hospital

Cuyahoga Falls, Ohio

Thomas Shipp, MD, RDMS

Brigham and Women's Hospital

Harvard Medical School

Boston, Massachusetts

Robert A. Sofferman, MD

Emeritus Professor of Surgery

Department of Surgery, Division of Otolaryngology

University of Vermont Medical Center

Burlington, Vermont

Collaborative Committee:

John Antonakis, MD
Portsmouth Regional Hospital
Staff Anesthesiologist
Portsmouth, New Hampshire

H. Jack Baskin, MD, MACE
Associate Professor of Medicine at University of Central Florida College of Medicine
Past President of the American College of Endocrinology
Orlando, Florida

Fred H. Brennan, Jr., DO, FAOASM, FAAFP, FACSM
Team Physician, University of New Hampshire
Seacoast Orthopedics and Sports Medicine
Somersworth, New Hampshire
Deputy Commander, 157th Medical Group, Pease Air National Guard Base
Portsmouth,New Hampshire

Victor Flores, MD
Rehabilitation Specialist
Plaza Medical Center of Fort Worth
Fort Worth, Texas

Lynwood Hammers, DO
Hammers Healthcare Imaging, LLC
Clinical Associate Professor
Departments of Radiology and Medicine
Yale University
New Haven, Connecticut

Daniel Haun, DC, DACBR
Assistant Professor, Basic Science, Clinical Science, and Chiropractic Science Divisions
Faculty, Department of Radiology
Logan University
Chesterfield, MO

Steve J. Leech, MD
Assistant Professor
Department of Emergency Medicine
Orlando Health
Orlando, Florida

Kenneth Mautner, MD
Assistant Professor of Orthopaedics
Department of Pain Management and Rehabilitation & Department of Orthopedics
Director of PCSM, Emory University School of Medicine
Atlanta, Georgia

Dolores B. Njoku, MD
Associate Professor
Division of Pediatric Anesthesiology/Critical Care Medicine
Department of Anesthesiology/Critical Care Medicine
Johns Hopkins University School of Medicine
Bloomberg Children's Center
Baltimore, MD

Christopher Sadler, MA, PA-C, CDE

Diabetes and Endocrine Associates

Past President: American Society of Endocrine Physician Assistants

La Jolla, CA

Lynn Reede, CRNA, DNP, MBA

Senior Director, Professional Practice

American Association of Nurse Anesthetists

Park Ridge, Illinois

Anthony M. Reginato, MD, PhD

Director, Rheumatology Research & Musculoskeletal Ultrasound

Associate Rheumatology Fellowship Program Director, Brown University

Acting Chief, Division of Rheumatology, Providence VAMC

University Medicine Foundation/RIH

Assistant Professor in Medicine

The Warren Alpert Medical School at Brown University

Providence, Rhode Island

Lisa J. Thiemann, PhD, CRNA

Chief Credentialing Officer

National Board of Certification and Recertification for Nurse Anesthetists

Chicago, Illinois

Douglas M. White, DPT, OCS, RMSK

Director of Physical Therapy

Milton Orthopaedic & Sports Physical Therapy, PC

Milton, Massachusetts

Original copyright 2014
Renamed 2015

References

1. American Institute of Ultrasound in Medicine. Official statements: training guidelines for physicians who evaluate and interpret diagnostic ultrasound examinations. American Institute of Ultrasound in Medicine website; 2014. http://www.aium.org/resources/statements.aspx.
2. American Institute of Ultrasound in Medicine. Standards and guidelines for the accreditation of ultrasound practices. American Institute of Ultrasound in Medicine website; 2014. http://www.aium.org/officialStatements/26.
3. American College of Radiology. ACR practice guideline for performing and interpreting diagnostic ultrasound examinations. In: *ACR Practice Guidelines and Technical Standards*. Reston, VA: American College of Radiology; 2006.
4. American Institute of Ultrasound in Medicine. AIUM practice guideline for the performance of a musculoskeletal ultrasound examination. *J Ultrasound Med* 2012; 31:1473–1488.
5. Smith J, Finnoff JT. Diagnostic and interventional musculoskeletal ultrasound: Part 1. Fundamentals. *PM R* 2009; 1:64–75
6. Smith J, Finnoff JT. Diagnostic and interventional musculoskeletal ultrasound: Part 2. Clinical applications. *PM R* 2009; 1:162–177.
7. Sites B, Spence B, Gallagher J, Wiley CW, Bertrand ML, Blike GT. Characterizing novice behavior associated with learning ultrasound-guided peripheral regional anesthesia. *Reg Anesth Pain Med* 2007; 32:107–115.
8. Sites BD, Macfarlane AJR, Sites VR, et al. Clinical sonopathology for the regional anesthesiologist. Part 2: bone, viscera, subcutaneous tissue and foreign bodies. *Reg Anesth Pain Med* 2010; 35:281–289.
9. Sites BD, Macfarlane AJR, Sites VR, et al. Clinical sonopathology for the regional anesthesiologist. Part 1: vascular and neural. *Reg Anesth Pain Med* 2010; 35:272–280.
10. Sites BD, Brull R, Chan VWS, et al. Artifacts and pitfall errors associated with ultrasound-guided regional anesthesia. Part II: a pictorial approach to understanding and avoidance. *Reg Anesth Pain Med* 2010; 35(suppl):S81–S92.
11. Sites BD, Brull R, Chan VWS, et al. Artifacts and pitfall errors associated with ultrasound-guided regional anesthesia. Part I: understanding the basic principles of ultrasound physics and machine operations. *Reg Anesth Pain Med* 2007; 32:412–418.
12. Tirado A, Nagdev A, Henningsen C, Breckon P, Chiles K. Ultrasound-guided procedures in the emergency department: needle guidance and localization. *Emerg Med Clin North Am* 2013; 31:87–115.
13. Sites BD, Chan VW, Neal JM, et al. The American Society for Regional Anesthesia and Pain Medicine and the European Society of Regional Anesthesia and Pain Therapy Joint Committee recommendations for education and training ultrasound-guided regional anesthesia. *Reg Anesth Pain Med* 2010; 35(suppl):S74–S80.
14. Malloy PC, Grassi CJ, Kundu S, et al. Consensus guidelines for periprocedural management of coagulation status and hemostasis risk in percutaneous image-guided interventions. *J Vasc Interv Radiol* 2009; 20(suppl):S240–S249.
15. Taninishi H, Morita K. Ultrasound-guided peripheral nerve blocks for a patient receiving four kinds of anticoagulant and antiplatelet drugs: a case report. *J Anesth* 2011; 25:318–320.
16. Levi DS. Intra-articular hip injections using ultrasound guidance: accuracy using a linear array transducer. *PM R* 2013; 5:129–134.
17. Auyong DB, Tokeshi J, Joshi S, Anderson CT. Recognition of an incidental abscess and hematoma during ultrasound-guided femoral nerve block. *Reg Anesth Pain Med* 2011; 36:406–409.
18. Centers for Disease Control and Prevention, Division of Healthcare Quality Promotion. Sterilization and disinfection of medical devices: general principles. Centers for Disease Control and Prevention website; 2003. http://www.cdc.gov/ncidod/hip/sterile/sterilgp.htm.

19. US Food and Drug Administration. ODE device evaluation information: FDA-cleared sterilants and high-level disinfectants with general claims for processing reusable medical and dental devices. US Food and Drug Administration website; March 2003. http://www.fda.gov/cdrh/ode/germlab.html.

20. Cervini P, Hesley GK, Thompson RL, Sampathkumar P, Knudsen JM. Incidence of infectious complications after an ultrasound-guided intervention. *AJR Am J Roentgenol* 2010; 195:846–850.

21. Lawrence MW, Blanks J, Ayala R, et al. Hospital-wide survey of bacterial contamination of point-of-care ultrasound probes and coupling gel. *J Ultrasound Med* 2014; 33:457–462.

22. Amis S, Ruddy M, Kibbler CC, Economides DL, MacLean AB. Assessment of condoms as probe covers for transvaginal sonography. *J Clin Ultrasound* 2000; 28:295–298.

23. Rooks VJ, Yancey MK, Elg SA, Brueske L. Comparison of probe sheaths for endovaginal sonography. *Obstet Gynecol* 1996; 87:27–29.

24. Milki AA, Fisch JD. Vaginal ultrasound probe cover leakage: implications for patient care. *Fertil Steril* 1998; 69:409–411.

25. Tsui BCH, Twomey C, Finucane BT. Visualization of the brachial plexus in the supraclavicular region using a curved ultrasound probe with a sterile transparent dressing. *Reg Anesth Pain Med* 2006; 31:182–184.

26. Jang SH, Lee SC, Lee JH, Nam SH, Cho KR, Park Y. Comparison of ultrasound (US)-guided intra-articular injections by in-plain and out-of-plain on medial portal of the knee. *Rheumatol Int* 2013; 33:1951–1959.

27. Wiesmann T, Borntrager A, Zoremba M, Neff M, Wulf H, Steinfeldt T. Compound imaging technology and echogenic needle design: effects on needle visibility and tissue imaging. *Reg Anesth Pain Med* 2013; 38:452–455.

28. Smith J, Wisniewski SJ, Finnoff JT, Payne JM. Sonographically guided carpal tunnel injections: the ulnar approach. *J Ultrasound Med* 2008; 27:1485–1490.

29. Deam RK, Kluger R, Barrington MJ, McCutcheon CA. Investigation of a new echogenic needle for use with ultrasound peripheral nerve blocks. *Anaesth Intensive Care* 2007; 35:582–586.

30. Daley EL, Bajaj S, Bisson LJ, et al. Improving injection accuracy of the elbow, knee, and shoulder: does injection site and imaging make a difference? A systematic review. *Am J Sports Med* 2011; 39:656–662.

31. Cunnington J, Marshall N, Hide G, et al. A randomized, double-blind, controlled study of ultrasound-guided corticosteroid injection into the joint of patients with inflammatory arthritis. *Arthritis Rheum* 2010; 62:1862–1869.

32. Soh E, Li W, Ong KO, Chen W, Bautista D. Image-guided versus blind corticosteroid injections in adults with shoulder pain: a systematic review. *BMC Musculoskelet Disord* 2011; 12:137.

33. Sibbitt WL Jr, Band PA, Chavez-Chiang NR, Delea SL, Norton HE, Bankhurst AD. A randomized controlled trial of the cost-effectiveness of ultrasound-guided intraarticular injection of inflammatory arthritis. *J Rheumatol* 2011; 38:252–263.

34. Berkoff DJ, Miller LE, Block JE. Clinical utility of ultrasound guidance for intra-articular knee injections: a review. *Clin Interv Aging* 2012; 7:89–95.

35. Bloom JE, Rischin A, Johnston RV, Buchbinder R. Image-guided versus blind glucocorticoid injection for shoulder pain. *Cochrane Database Syst Rev* 2012; 8:CD009147.

36. Choudur HN, Ellins ML. Ultrasound-guided gadolinium joint injections for magnetic resonance arthrography. *J Clin Ultrasound* 2011; 39:6–11.

37. Curtiss HM, Finnoff JT, Peck E, Hollman J, Muir J, Smith J. Accuracy of ultrasound-guided and palpation-guided knee injections by an experienced and less-experienced injector using a superolateral approach: a cadaveric study. *PM R* 2011; 3:507–515.

38. Gokalp G, Dusak A, Yazici Z. Efficacy of ultrasonography-guided shoulder MR arthrography using a posterior approach. *Skeletal Radiol* 2010; 39:575–579.

39. Kantarci F, Ozbayrak M, Gulsen F, Gencturk M, Botanlioglu H, Mihmanli I. Ultrasound-guided injection for MR arthrography of the hip: comparison of two different techniques. *Skeletal Radiol* 2013; 42:37–42.

40. Migliore A, Granata M, Tormenta S, et al. Hip viscosupplementation under ultra-sound guidance reduces NSAID consumption in symptomatic hip osteoarthritis patients in a long follow-up. Data from Italian registry. *Eur Rev Med Pharmacol Sci* 2011; 15:25–34.

41. Park Y, Choi WA, Kim YK, Lee SC, Lee JH. Accuracy of blind versus ultrasound-guided suprapatellar bursal injection. *J Clin Ultrasound* 2012; 40:20–25.

42. Park Y, Lee SC, Nam HS, Lee J, Nam SH. Comparison of sonographically guided intra-articular injections at 3 different sites of the knee. *J Ultrasound Med* 2011; 30:1669–1676.

43. Patel DN, Nayyar S, Hasan S, Khatib O, Sidash S, Jazrawi LM. Comparison of ultrasound-guided versus blind glenohumeral injections: a cadaveric study. *J Shoulder Elbow Surg* 2012; 21:1664–1668.

44. Pourbagher MA, Ozalay M, Pourbagher A. Accuracy and outcome of sonographically guided intra-articular sodium hyaluronate injections in patients with osteoarthritis of the hip. *J Ultrasound Med* 2005; 24:1391–1395.

45. Rutten MJ, Collins JM, Maresch BJ, et al. Glenohumeral joint injection: a comparative study of ultrasound and fluoroscopically guided techniques before MR arthrography. *Eur Radiol* 2009; 19:722–730.

46. Smith J, Hurdle MF, Weingarten TN. Accuracy of sonographically guided intra-articular injections in the native adult hip. *J Ultrasound Med* 2009; 28:329–335.

47. Souza PM, Aguiar RO, Marchiori E, Bardoe SA. Arthrography of the shoulder: a modified ultrasound-guided technique of joint injection at the rotator interval. *Eur J Radiol* 2010; 74:e29–e32.

48. Valls R, Melloni P. Sonographic guidance of needle position for MR arthrography of the shoulder. *AJR Am J Roentgenol* 1997; 169:845–847.

49. Zufferey P, Revaz S, Degailler X, Balague F, So A. A controlled trial of the benefits of ultrasound-guided steroid injection for shoulder pain. *Joint Bone Spine* 2012; 79:166–169.

50. Balint PV, Kane D, Hunter J, McInnes IB, Field M, Sturrock RD. Ultrasound-guided versus conventional joint and soft tissue fluid aspiration in rheumatology practice: a pilot study. *J Rheumatol* 2002; 29:2209–2213.

51. Sage W, Pickup L, Smith TO, Denton ER, Toms AP. The clinical and functional outcomes of ultrasound-guided vs landmark-guided injections for adults with shoulder pathology: a systematic review and meta-analysis. *Rheumatology* 2013; 52:743–751.

52. Sibbitt WL Jr, Band PA, Kettwich LG, Chavez-Chiang NR, Delea SL, Bankhurst AD. A randomized controlled trial evaluating the cost-effectiveness of sonographic guidance for intra-articular injection of the osteoarthritic knee. *J Clin Rheumatol* 2011; 17:409–415.

53. Sibbitt WL Jr, Kettwich LG, Band PA, et al. Does ultrasound guidance improve the outcomes of arthrocentesis and corticosteroid injection of the knee? *Scand J Rheumatol* 2012; 41:66–72.

54. Soh E, Li W, Ong KO, Chen W, Bautista D. Image-guided versus blind corticosteroid injections in adults with shoulder pain: a systematic review. *BMC Musculoskelet Disord* 2011; 12:137.

55. Drakonaki EE, Kho JS, Sharp RJ, Ostlere SJ. Efficacy of ultrasound-guided steroid injections for pain management of midfoot joint degenerative disease. *Skeletal Radiol* 2011; 40:1001–1006.

56. Khosla S, Thiele R, Baumhauer JF. Ultrasound guidance for intra-articular injections of the foot and ankle. *Foot Ankle Int* 2009; 30:886–890.

57. Smith J, Brault JS, Rizzo M, Sayeed YA, Finnoff JT. Accuracy of sonographically guided and palpation guided scaphotrapeziotrapezoid joint injections. *J Ultrasound Med* 2011; 30:1509–1515.

58. Smith J, Finnoff JT, Henning PT, Turner NS. Accuracy of sonographically guided posterior subtalar joint injections: comparison of 3 techniques. *J Ultrasound Med* 2009; 28:1549–1557.

59. Smith J, Finnoff JT, Levy BA, Lai JK. Sonographically guided proximal tibiofibular joint injection: technique and accuracy. *J Ultrasound Med* 2010; 29:783–789.

60. Smith J, Rizzo M, Sayeed YA, Finnoff JT. Sonographically guided distal radioulnar joint injection: technique and validation in a cadaveric model. *J Ultrasound Med* 2011; 30:1587–1592.

61. Wisniewski SJ, Smith J, Patterson DG, Carmichael SW, Pawlina W. Ultrasound-guided versus nonguided tibiotalar joint and sinus tarsi injections: a cadaveric study. *PM R* 2010; 2:277–281.

62. Raza K, Lee CY, Pilling D, et al. Ultrasound guidance allows accurate needle placement and aspiration from small joints in patients with early inflammatory arthritis. *Rheumatology* (*Oxford*) 2003; 42:976–979.

63. Umphrey GL, Brault JS, Hurdle MF, Smith J. Ultrasound-guided intra-articular injection of the trapeziometacarpal joint: description of technique. *Arch Phys Med Rehabil* 2008; 89:153–156.

64. Chen MJ, Lew HL, Hsu TC, et al. Ultrasound-guided shoulder injections in the treatment of subacromial bursitis. *Am J Phys Med Rehabil* 2006; 85:31–35.

65. Di Sante L, Paoloni M, Ioppolo F, Dimaggio M, Di Renzo S, Santilli V. Ultrasound-guided aspiration and corticosteroid injection of Baker's cysts in knee osteoarthritis: a prospective observational study. *Am J Phys Med Rehabil* 2010; 89:970–975.

66. Dogu B, Yucel SD, Sag SY, Bankaoglu M, Kuran B. Blind or ultrasound-guided corticosteroid injections and short-term response in subacromial impingement syndrome: a randomized, double-blind, prospective study. *Am J Phys Med Rehabil* 2012; 91:658–665.

67. Ekeberg OM, Bautz-Holter E, Tveita EK, Juel NG, Kvalheim S, Brox JI. Subacromial ultrasound guided or systemic steroid injection for rotator cuff disease: randomised double blind study. *BMJ* 2009; 338:a3112.

68. Epis O, Bruschi E. Interventional ultrasound: a critical overview on ultrasound-guided injections and biopsies. *Clin Exp Rheumatol* 2014; 32:S78–S84.

69. Moss SG, Schweitzer ME, Jacobson JA, et al. Hip joint fluid detection and distribution at MR imaging and US with cadaveric correlation. *Radiology* 1998; 208:43–48.

70. De Maeseneer M, Jacobson JA, Jaovisidha S, et al. Elbow effusions: distribution of joint fluid with flexion and extension and imaging implications. *Invest Radiol* 1998; 33:117–125.

71. Im SH, Lee SC, Park YB, Cho SR, Kim JC. Feasibility of sonography for intra-articular injections in the knee through a medial patellar portal. *J Ultrasound Med* 2009; 28:1465–1470.

72. Rajeswaran G, Lee JC, Eckersley R, Katsarma E, Healy JC. Ultrasound-guided percutaneous release of the annular pulley in trigger digit. *Eur Radiol* 2009; 19:2232–2237.

73. Rojo-Manaute J, Rodriguez-Maruri G, Capa-Grasa A, Chana-Rodriguez F, Soto-Mdel V, Martin JV. Sonographically guided intrasheath percutaneous release of the first annular pulley for trigger digits, part 1: clinical efficacy and safety. *J Ultrasound Med* 2012; 31:417–424.

74. Rojo-Manaute J, Capa-Grasa A, DelCerro-Gutierrez M, Martinez MV, Chana-Rodriguez F, Martin JV. Sonographically guided intrasheath percutaneous release of the first annular pulley for trigger digits, part 2: randomized comparative study of the economic impact of 3 surgical models. *J Ultrasound Med* 2012; 31:427–438.

75. Smith J, Rizzo M, Lai JK. Sonographically guided percutaneous first annular pulley release: cadaveric safety study of needle and knife techniques. *J Ultrasound Med* 2010; 29:1531–1542.

76. Chen H, Takemoto R, Hata J. Ultrasound-guided piriformis injection with confirmation of needle placement through electromyography. *Pain Med* 2012; 13:978–979.

77. Finnoff JT, Fowler SP, Lai JK, et al. Treatment of chronic tendinopathy with ultrasound-guided needle tenotomy and platelet-rich plasma injection. *PM R* 2011; 3:900–911.

78. Finnoff JT, Hurdle MF, Smith J. Accuracy of ultrasound-guided versus fluoroscopically guided contrast-controlled piriformis injections: a cadaveric study. *J Ultrasound Med* 2008; 27:1157–1163.

79. Hashiuchi T, Sakurai G, Morimoto M, Komei T, Takakura Y, Tanaka Y. Accuracy of the biceps tendon sheath injection: ultrasound-guided or unguided injection? A randomized controlled trial. *J Shoulder Elbow Surg* 2011; 20:1069–1073.

80. Housner JA, Jacobson JA, Misko R. Sonographically guided percutaneous needle tenotomy for the treatment of chronic tendinosis. *J Ultrasound Med* 2009; 28:1187–1192.

81. Kume K, Amano K, Yamada S, Amano K, Kuwaba N, Ohta H. In de Quervain's with a separate EPB compartment, ultrasound-guided steroid injection is more effective than a clinical injection technique: a prospective open-label study. *J Hand Surg Eur Vol* 2012; 37:523–527.

82. Lee DH, Han SB, Park JW, Lee SH, Kim KW, Jeong WK. Sonographically guided tendon sheath injections are more accurate than blind injections: implications for trigger finger treatment. *J Ultrasound Med* 2011; 30:197–203.

83. McDermott JD, Ilyas AM, Nazarian LN, Leinberry CF. Ultrasound-guided injections for de Quervain's tenosynovitis. *Clin Orthop Relat Res* 2012; 470:1925–1931.

84. Muir JJ, Curtiss HM, Hollman J, Smith J, Finnoff JT. The accuracy of ultrasound-guided and palpation-guided peroneal tendon sheath injections. *Am J Phys Med Rehabil* 2011; 90:564–571.

85. Smith J, Finnoff JT, Santaella-Sante B, Henning T, Levy BA, Lai JK. Sonographically guided popliteus tendon sheath injection: techniques and accuracy. *J Ultrasound Med* 2010; 29:775–782.

86. Smith J, Hurdle MF, Locketz AJ, Wisniewski SJ. Ultrasound-guided piriformis injection: technique description and verification. *Arch Phys Med Rehabil* 2006; 87:1664–1667.

87. Smith J, Wisniewski SJ, Wempe MK, Landry BW, Sellon JL. Sonographically guided obturator internus injections: techniques and validation. *J Ultrasound Med* 2012; 31:1597–1608.

88. Tsai WC, Hsu CC, Chen CP, Chen MJ, Yu TY, Chen YJ. Plantar fasciitis treated with local steroid injection: comparison between sonographic and palpation guidance. *J Clin Ultrasound* 2006; 34:12–16.

89. Yucel I, Yazici B, Degirmenci E, Erdogmus B, Dogan S. Comparison of ultrasound-, palpation-, and scintigraphy-guided steroid injections in the treatment of plantar fasciitis. *Arch Orthop Trauma Surg* 2009; 129:695–701.

90. Connell D, Ali KE, Ahmad M, Lambert S, Corbett S, Curtis M. Ultrasound-guided autologous blood injection for tennis elbow. *Skeletal Radiol* 2006; 35:371–377.

91. Dragoo J, Wasterlain AS, Braun HJ, Nead KT. Platelet-rich plasma as a treatment for patellar tendinopathy: a double-blind, randomized controlled trial. *Am J Sports Med* 2014; 42:610–618.

92. Filardo G, Kon E, DiMatteo B, Pelotti P, DiMartino A, Marcacci M. Platelet-rich plasma for the treatment of patellar tendinopathy: clinical and imaging findings at medium-term follow-up. *Int Orthop* 2013; 37:1583–1589.

93. Gaweda K, Tarczynska M, Krzyzanowski W. Treatment of Achilles tendinopathy with platelet-rich plasma. *Int J Sports Med* 2010; 31:577–583.

94. James S, Ali K, Pocock C, Robertson C, Walter J, Bell J, Connell D. Ultrasound-guided dry needling and autologous blood injection for patellar tendinosis. *Br J Sports Med* 2007; 41:518–521.

95. Kim E, Lee JH. Autologous platelet-rich plasma versus dextrose prolotherapy for the treatment of chronic recalcitrant plantar fasciitis. *PM R* 2013; 6:152–158.

96. Podesta L, Crow SA, Volkmer D, Bert T, Yocum LA. Treatment of partial ulnar collateral ligament tears in the elbow with platelet-rich plasma. *Am J Sports Med* 2013; 41:1689–1694.

97. Suresh S, Ali KE, Jones H, Connell DA. Medial epicondylitis: is ultrasound-guided autologous blood injection an effective treatment? *Br J Sports Med* 2006; 40:935–939.

98. Thanasas C, Papadimitriou G, Charalambidis C, Paraskevopoulos I, Papanikolaou A. Platelet-rich plasma versus autologous whole blood for the treatment of chronic lateral elbow epicondylitis: a randomized controlled clinical trial. *Am J Sports Med* 2011; 39:2130–3134.

99. Campbell K, Boykin RE, Wijdicks CA, Erik-Giphart J, LaPrade RF, Philippon MJ. Treatment of hip capsular injection in a professional soccer player with platelet rich plasma and bone marrow aspirate concentrate therapy. *Knee Surg Sports Traumatol Arthrosc* 2013; 21:1684–1688.

100. Connell D, Datir A, Alyas F, Curtis M. Treatment of lateral epicondylitis using skin-derived tenocyte-like cells. *Br J Sports Med* 2009; 43:293–298.

101. Obaid H, Clarke A, Rosenfeld P, Leach C, Connell D. Skin-derived fibroblasts for the treatment of refractory Achilles tendinosis: preliminary short-term results. *J Bone Joint Surg Am* 2012; 94:193–200.

102. Wang A, Breidahl W, Mackie KE, et al. Autologous tenocyte injection for the treatment of severe chronic resistant lateral epicondylitis: a pilot study. *Am J Sports Med* 2013; 41:2925–2932.

103. Blankenbaker D, DeSmet AA, Keene JS. Sonography of the iliopsoas tendon and injection of the iliopsoas bursa for diagnosis and management of the painful snapping hip. *Radiology* 2006; 35:565–571.

104. Connell D, Ali KE, Ahmad M, Lambert S, Corbett S, Curtis M. Ultrasound-guided autologous blood injection for tennis elbow. *Skeletal Radiol* 2006; 35:371–377.

105. McShane J, Nazarian LN, Harwood MI. Sonographically guided percutaneous needle tenotomy for treatment of common extensor tendinosis in the elbow. *J Ultrasound Med* 2006; 25:1281–1289.

106. McShane JM, Shah VN, Nazarian LN. Sonographically guided percutaneous needle tenotomy for treatment of common extensor tendinosis in the elbow: is a corticosteroid necessary? *J Ultrasound Med* 2008; 27:1137–1144.

107. Chiavaras M, Jacobson JA. Ultrasound-guided tendon fenestration. *Semin Muscuoloskelet Radiol* 2013; 17:85–90.

108. Maffulli N, Oliva F, Testa V, Capasso G, DelBuono A. Multiple percutaneous longitudinal tenotomies for chronic Achilles tendinopathy in runners: a long-term study. *Am J Sports Med* 2013; 41:2151–2157.

109. Koh J, Mohan PC, Howe TS, et al. Fasciotomy and surgical tenotomy for recalcitrant lateral elbow tendinopathy: early clinical experience with a novel device for minimally invasive percutaneous microresection. *Am J Sports Med* 2013; 41:636–644.

110. Barnes DE, Beckley JM, Smith J. Percutaneous ultrasonic tenotomy for chronic elbow tendinosis: a prospective study [published online ahead of print October 8, 2014]. *J Shoulder Elbow Surg* doi:10.1016/j.jse.2014.07.017.

111. McShane J, Slaff S, Gold JE, Nazarian LN. Sonographically guided percutaneous needle release of the carpal tunnel for treatment of carpal tunnel syndrome. *J Ultrasound Med* 2012; 31:1341–1349.

112. Mulvaney S. Ultrasound-guided percutaneous neuroplasty of the lateral femoral cutaneous nerve for the treatment of meralgia paresthetica: a case report and description of a new ultrasound-guided technique. *Curr Sports Med Rep* 2011; 10:99–104.

113. Sampson S, Meng M, Schulte A, Trainor D, Montenegro R, Aufiero D. Management of Dupytren contracture with ultrasound-guided lidocaine injection and needle aponeurotomy coupled with osteopathic manipulative treatment. *J Am Osteopath Assoc* 2011; 111:113–116.

114. Buncke G, McCormack B, Bodor M. Ultrasound-guided carpal tunnel release using the Manos CTR system. *Microsurgery* 2013; 33:362–366.

115. de-la-Fuenta J, Miguel-Perez MI, Balius R, Guerrero V, Michaud J, Bong D. Minimally invasive ultrasound-guided carpal tunnel release: a cadaver study. *J Clin Ultrasound* 2013; 41:101–107.

116. Lecoq B, Hanouz N, Vielpeau C, Marcelli C. Ultrasound-guided percutaneous surgery for carpal tunnel syndrome: a cadaver study. *Joint Bone Spine* 2011; 78:516–518.

117. Nakamichi K, Tachibana S, Yamamoto S, Ida M. Percutaneous carpal tunnel release compared with mini-open release using ultrasonic guidance for both techniques. *J Hand Surg Am* 2010; 35:437–445.

118. Rojo-Manaute J, Capa-Grasa A, Rodriguez-Maruri GE, Moran LM, Martinez MV, Martin JV. Ultra–minimally invasive sonographically guided carpal tunnel release: anatomic study of a new technique. *J Ultrasound Med* 2013; 32:131–142.

119. Farin PU, Rasanen H, Jaroma H, Harju A. Rotator cuff calcifications: treatment with ultrasound-guided percutaneous needle aspiration and lavage. *Skeletal Radiol* 1996; 25:551–554.

120. Yoo JC, Koh KH, Park WH, Park JC, Kim SM, Yoon YC. The outcome of ultrasound-guided needle decompression and steroid injection in calcific tendinitis. *J Shoulder Elbow Surg* 2010; 19:596–600.

121. deWitte P, Selten JW, Navas A, et al. Calcific tendinitis of the rotator cuff: a randomized controlled trial of ultrasound-guided needling and lavage versus subacromial steroids. *Am J Sports Med* 2013; 41: 1665–1673.

122. DeZordo T, Ahmad N, Odegaard F, et al. US-guided therapy of calcific tendinopathy: clinical and radiological outcome assessment in shoulder and non-shoulder tendons. *Ultraschall Med* 2011; 32(suppl 1): S117–S123.

123. Sconfienza L, Vigano S, Martini C, et al. Double-needle ultrasound-guided percutaneous treatment of rotator cuff calcific tendinitis: tips & tricks. *Skeletal Radiol* 2013; 42:19–24.

124. Serafini G, Sconfienza LM, Lacelli F, Silvestri E, Aliprandi A, Sardanelli F. Rotator cuff calcific tendonitis: short-term and 10-year outcome after two-needle US-guided percutaneous treatment—nonrandomized controlled trial. *Radiology* 2010; 252:157–164.

125. Kalichman L, Vulfsons S. Dry needling in the management of musculoskeletal pain. *J Am Board Fam* Med 2010; 23:640–646.

126. Ballyns J, Shah JP, Hammond J, Gebreab T, Gerber LH, Sikdar S. Objective sonographic measures for characterizing myofascial trigger points associated with cervical pain. *J Ultrasound Med* 2011; 30: 1331–1340.

127. Alfredson H, Lorentzon R. Sclerosing polidocanol injections of small vessels to treat the chronic painful tendon. *Cardiovasc Hematol Agents Med Chem* 2007; 5:97–100.

128. American College of Radiology. ACR-SIR practice guideline for specifications and performance of image-guided percutaneous drainage/aspiration of abscesses and fluid collections (PDAFC) in adults. In: *ACR Practice Guidelines and Technical Standards*. Reston, VA; American College of Radiology; 2008.

129. Barr L, Hatch N, Roque PJ, Wu TS. Basic ultrasound-guided procedures. *Crit Care Clin* 2014; 30:275–304.

130. Peng WH, Narouze S. Ultrasound-guided interventional procedures in pain medicine: a review of anatomy, sonoanatomy and procedures. Part I: non-axial structures. *Reg Anesth Pain Med* 2009; 34:458–474.

131. Fingerman M, Benonis JG, Martin G. A practical guide to commonly performed ultrasound-guided peripheral nerve blocks. *Curr Opin Anaesthesiol* 2009; 22:600–607.

132. Choquet O, Morau D, Biboulet P, Capdevila X. Where should the tip of the needle be located in ultrasound-guided peripheral nerve blocks? *Curr Opin Anaesthesiol* 2012; 25:596–602.

133. Narouze SN, Provenzano DA. Sonographically guided cervical facet nerve and joint injections: why sonography? *J Ultrasound Med* 2013; 32:1885–1896.

134. Provenzano DA, Narouze SN. Sonographically guided lumbar spine procedures. *J Ultrasound Med* 2013; 32:1109–1116.

135. Hartung W, Ross CJ, Straub R, et al. Ultrasound-guided sacroiliac joint injection in patients with established sacroiliitis: precise IA injection verified by MRI scanning does not predict clinical outcome. *Rheumatology* 2010; 49:1479–1482.

136. Migliore A, Bizzi E, Massafra U, et al. A new technical contribution for ultrasound-guided injections of sacroiliac joints. *Eur Rev Med Pharmacol Sci* 2010; 14:465–469.

137. Lewis BD, Charboneau JW, Reading CC. Ultrasound-guided biopsy and ablation in the neck. *Ultrasound Q* 2002; 18:3–12.

138. American College of Radiology. ACR-SIR practice guideline for the reporting and archiving of interventional radiology procedures. In: *ACR Practice Guidelines and Technical Standards*. Reston, VA: American College of Radiology; 2009.