AIUM Practice Guideline for the Performance of the Ultrasound Examination for Detection of Developmental Dysplasia of the Hip

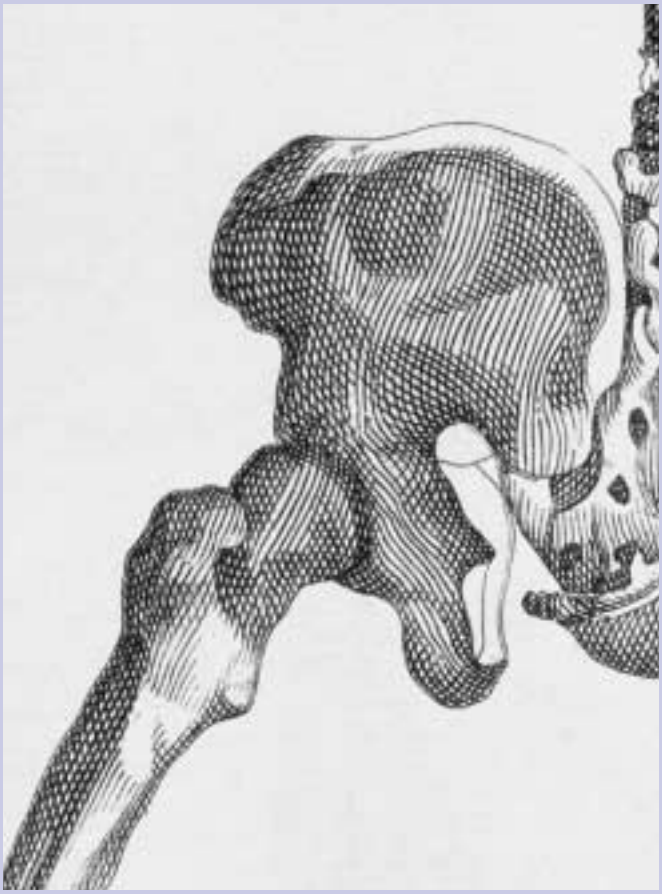

©1999 Visual Language

American Institute of Ultrasound in Medicine

© 2003 by the American Institute of Ultrasound in Medicine

The American Institute of Ultrasound in Medicine (AIUM) is an educational, scientific, and professional society concerned with the advancement of the art and science of ultrasound in medicine and research. To promote this mission, the AIUM is pleased to publish, in conjunction with the American College of Radiology (ACR), this new Guideline for the Performance of the Ultrasound Examination for Detection of Developmental Dysplasia of the Hip. We are indebted to the many volunteers who contributed their time, knowledge, and energy to bringing this document to completion.

The AIUM represents the entire range of clinical and basic science interests in medical diagnostic ultrasound, and, with hundreds of volunteers, the AIUM has promoted the safe and effective use of ultrasound in clinical medicine for 50 years. This document, and others like it, will continue to advance this mission.

Clinical standards and practice guidelines of the AIUM are intended to provide the medical ultrasound community with guidelines for the performance and recording of high-quality ultrasound examinations. The standards and guidelines reflect what the AIUM considers the minimum criteria for a complete examination in each area but are not intended to establish a legal standard of care. AIUM-accredited practices are expected to generally follow the standards and guidelines with the recognition that deviations from the standards and guidelines will be needed in some cases, depending on patient needs and available equipment. Practices are encouraged to go beyond the standards and guidelines to provide additional service and information as needed by their referring physicians and patients.

AMERICAN INSTITUTE OF
ULTRASOUND IN MEDICINE
14750 Sweitzer Lane, Suite 100
Laurel, Maryland 20707-5906
301-498-4100

I. Introduction

The clinical aspects of this guideline (Introduction, Indications/Contraindications, Specifications of the Examination, and Equipment Specifications) were developed collaboratively by the American Institute of Ultrasound in Medicine (AIUM) and the American College of Radiology (ACR). Recommendations for physician requirements, procedure documentation, and quality control vary between the 2 organizations and are addressed by each separately.

This guideline has been developed to assist practitioners performing sonographic studies for detection of developmental dysplasia of the hip (DDH). (The term DDH has replaced the term congenital dysplasia [dislocation] of the hip [CDH].) Adherence to the following guideline will maximize the probability of detecting most of the abnormalities that relate to hip position, hip stability, and development of the acetabulum.

Ultrasound is an excellent method for diagnostic imaging of the immature hip. It affords direct visualization of the cartilaginous components of the hip joint. The value of ultrasound diminishes as the femoral head ossifies. For patients between 6 months and 1 year of age, radiography becomes more reliable. Usually by 1 year of age, the femoral head is sufficiently ossified to prevent good visualization of the acetabulum with ultrasound.

II. Indications/Contraindications

Ultrasound of the infant hip can be used both in the diagnosis of DDH and in monitoring treatment (when performed using customary splint-type devices).

Clinical indications for ultrasound of the infant hip[1] include but are not limited to

1. Abnormal findings on physical exam of the hip.
2. Family history of DDH.
3. Breech presentation at birth.
4. Postural molding conditions (torticollis, foot deformity).
5. Monitoring of treatment of DDH.

There are no absolute contraindications to ultrasound of the infant hip for DDH, but as discussed above, the study becomes less reliable relative to radiography as ossification of the femoral head progresses. Due to the presence of physiologic laxity, imaging is usually not performed on patients less than 2 weeks old.[3]

III. Qualifications and Responsibilities of Personnel

See the AIUM Official Statement: *Training Guidelines for Physicians Who Evaluate and Interpret Diagnostic Ultrasound Examinations* and the *AIUM Standards and Guidelines for the Accreditation of Ultrasound Practices*.

IV. Specifications of the Examination

The diagnostic examination for DDH incorporates 2 orthogonal planes. It is customary to examine both hips. The diagnostic exam should include a coronal view in the standard plane at rest and a transverse view of the flexed hip with and without stress. This enables an assessment of hip position, stability, and morphology when the study is correctly performed and interpreted. It is acceptable to perform the standard exam with the infant in a supine or lateral position. It should be noted that additional views and maneuvers can be obtained and that these may enhance the confidence of the examiner. Morphology is assessed at rest. Stress maneuvers follow those prescribed in the clinical examination of the hip (Barlow and Ortolani tests) and assess femoral stability. It is important that the infant be relaxed when hips are assessed for instability. Feeding the infant during the examination can increase patient comfort and cooperation.

A. Coronal View

The anatomic coronal plane is approximately parallel to the posterior skin sur-

face of an infant. If the superior edge of the transducer is rotated 10 to 15 degrees (usually posteriorly) into an oblique coronal plane, the ilium will appear straight, and after adjustment to assure that the imaging plane is through the deepest part of the acetabulum, the resulting image will be a coronal view in the standard plane.

The standard plane is defined by identification of a straight iliac line, the tip of the acetabular labrum, and transition from the os ilium to the triradiate cartilage (see Figure 1). Since the femoral head is almost spherical, the position of the femur is unimportant in this view, but the view is obtained most easily with the femur in a neutral position. The coronal view in the standard plane at rest can be performed with the hip in the flexed position during treatment. Femoral head position and displacement are noted. Acetabular morphology is assessed in this view. Validation by measurement is optional. Performance of stress in this view is optional.

B. Transverse Flexion View

The examination is performed with the hip flexed. The hip is tested for position at rest with passive abduction and adduction. This is followed by the application of gentle stress to assess stability. (Caution: Application of stress is omitted when hips are being examined during treatment.) The transverse plane is the anatomic transverse or axial plane (similar to the plane of a primary computed tomography image). The transverse view is obtained when the femur is in flexion and the transducer is in the transverse plane (Figure 2). The transducer is posterolateral so that imaging can be accomplished while the hip is abducted and adducted (Ortolani and Barlow maneuvers). The hip should be evaluated with the femur in flexion, at rest, and during application of gentle posteriorly directed force (stress) to assess stability. If the relationship of the femoral head to the posterior acetabulum changes with gentle stress, the hip is unstable. Other orthopedic stress maneuvers described in the literature are optional.

C. Modification of the Diagnostic Examination

The supervising physician may modify the examination depending on clinical circumstances, such as during or following treatment for DDH.

In such cases, a coronal view in the standard plane can be performed, and, if abnormal, a complete diagnostic examination is recommended.

V. Documentation

Adequate documentation is essential for high-quality patient care. There should be a permanent record of the sonographic examination and its interpretation. Comparison with prior relevant imaging studies is recommended when these are available. Images can be recorded in any of the standard storage formats. When optional measurements are performed, it is essential that they be obtained from images that meet the criteria for a standard plane. Images should be labeled with the examination date, patient identification, hip being imaged, image orientation, and whether stress is being applied. A report of the sonographic findings should be included in the patient's medical record, indicating acetabular morphology, position of femoral head, and stability. Retention of the sonographic examination should be consistent both with clinical needs and with relevant legal and local health care facility requirements.

Reporting should be in accordance with the *AIUM Standard for Documentation of an Ultrasound Examination*.

VI. Equipment Specifications

Hip ultrasound for the detection of developmental dysplasia of the hip should be performed with the highest frequency transducer that permits penetration of the soft tissues. Broadband linear transducers are preferable. Acetabular measurements should be made only on images produced with a linear transducer. Total ultrasound exposure should be kept as low as reasonably achievable (ALARA), while optimizing diagnostic information.

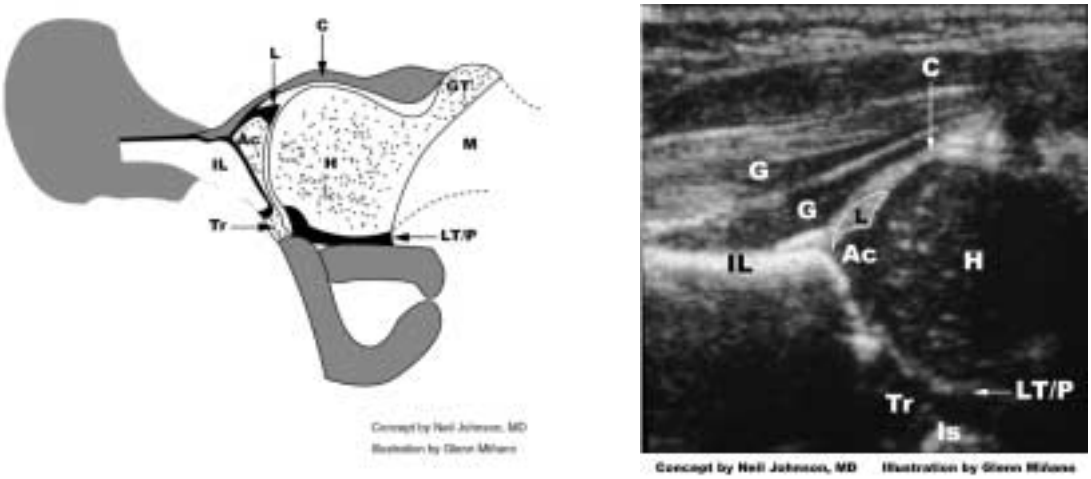

Figure 1. Coronal view of left hip joint in the standard plane. The femoral shaft is in the position of rest (usually 15–20 degrees of hip flexion).

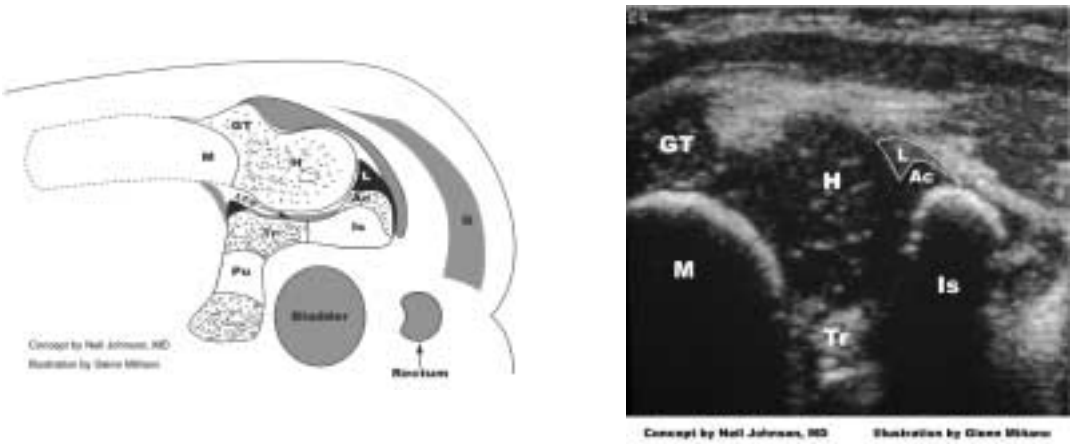

Figure 2. Transverse view of the left hip with the femoral shaft flexed 90 degrees at the hip.

Ac, acetabular cartilage; C, capsule; G, gluteus muscles; GT, greater trochanter; H, cartilaginous femoral head; IL, ilium; Is, ischium; L, labrum; LT/P, ligamentum teres/pulvinar complex; M, femoral metaphysis; Pu, pubis; Tr, triradiate cartilage

VII. Quality Control and Improvement, Safety, Infection Control, and Patient Education Concerns

Policies and procedures related to quality, patient education, infection control, and safety should be developed and implemented in accordance with the *AIUM Standards and Guidelines for the Accreditation of Ultrasound Practices*. Equipment performance monitoring should be in accordance with the *AIUM Standards and Guidelines for the Accreditation of Ultrasound Practices*.

Acknowledgments

This guideline was developed by the American Institute of Ultrasound in Medicine (AIUM), in collaboration with the American College of Radiology (ACR), according to the process described in the *ACR Practice Guidelines and Technical Standards Book*.

Collaborative Subcommittee

AIUM
Harriet Paltiel MD, Chair
Henrietta Kotlus-Rosenberg, MD
Howard T. Harcke, Jr, MD

ACR
Lori L. Barr, MD
Carrie Ruzal-Shapiro, MD
Barbara J. Wolfson, MD

AIUM Clinical Standards Committee
Brian Garra, MD, Chair
Jon Meilstrup, MD, Vice Chair
Bryann Bromley, MS, MD
Terry DuBose, MS, RDMS
Mary Frates, MD
Pat Fulgham, MD
Edward Grant, MD
Kim Gregory, MD
Barbara Hertzberg, MD
Lyndon Hill, MD
Wesley Lee, MD
John McGahan, MD
Michael McNamara, MD
Ellen Mendelson, MD
Laurence Needleman, MD
Karen Ophir, RDMS
Carl Otto, MD
Harriet Paltiel, MD
John Pellerito, MD
Cindy Rapp, BS, RDMS, RDCS

References

1. Aronsson DD, Goldberg MJ, Kling TF, et al. Developmental dysplasia of the hip. Pediatrics 1994; 94:201–208.
2. Barlow TG. Early diagnosis and treatment of congenital dislocation of the hip. J Bone Joint Surg Br 1962; 44-B:292–301.
3. American Academy of Pediatrics. Clinical practice guidelines: early detection of developmental dysplasia of the hip. Committee on quality improvement, subcommittee on developmental dysplasia of the hip. Pediatrics 2000; 105:896–905.
4. Eastwood DM. Neonatal hip screening. Lancet 2003; 361:595–597.
5. Graf R, Tschauner C, Klapsch W. Progress in prevention of late developmental dislocation of the hip by sonographic newborn hip "screening": results of a comparative follow-up study. J Pediatr Orthop 1993; B2:115–121.
6. Graf R. Hip sonography, how reliable? Sector scanning versus linear scanning? Dynamic versus static examination? Clin Orthop 1992; 18–21.
7. Grissom LE, Harcke HT, Kumar SJ, et al. Ultrasound evaluation of hip position in the Pavlik harness. J Ultrasound Med 1988; 7:1–6.
8. Hangen DH, Kasser JR, Emans JB, et al. The Pavlik harness and developmental dysplasia of the hip: has ultrasound changed treatment patterns? J Pediatr Orthop 1995; 15:729–735.
9. Harcke HT, Grissom LE. Performing dynamic sonography of the infant hip. AJR Am J Roentgenol 1990; 155:837–844.
10. Harcke HT. The role of ultrasound in the diagnosis and management of developmental dysplasia of the hip (DDH). Pediatr Radiol 1995; 25:225–227.
11. Keller MS, Weltin GG, Rattner Z, et al. Normal instability of the hip in the neonate: US standards. Radiology 1988; 169:733–736.
12. Rosendahl K, Markestad T, Lie RT. Ultrasound screening for developmental dysplasia of the hip in the neonate: the effect on treatment rate and prevalence of late cases. Pediatrics 1994; 94:47–52.
13. Rosenberg HK. Neonatal hip dislocation. In: Bluth EI, Benson C, Arger P, eds. The practice of ultrasonography. New York, NY: Thieme Publishers 2000: 488–502.
14. Rosendahl K, Aslaksen A, Lie RT, et al. Reliability of ultrasound in the early diagnosis of developmental dysplasia of the hip. Pediatr Radiol 1995; 25: 219–224.
15. Zieger M, Schulz RD. Ultrasonography of the infant hip, III: clinical application. Pediatr Radiol 1987; 17:226–232.