



# Case Study Submission Requirements: Reproductive Endocrinology and Infertility (REI) with Adjunct Competence in 3D

➤ Refer to the *Accreditation Application Manual* for [additional case study submission requirements](#).

**GYN cases in which a patient has had an oophorectomy are not acceptable for submission.**

## From your main site:

- submit a total of 2 complete standard TRANSVAGINAL gynecologic cases with their corresponding final reports which include a demonstration and interpretation of the additional 3D images referenced below

\* [3D Image Requirements & Acquisition/Submission Demonstration](#) ([← click me](#))

- **Image 1:** Acquisition image demonstrating the uterus in three orthogonal planes.
- **Image 2:** Reconstructed CORONAL view of the uterus in a single image.

- and -

- submit 2 complete TRANSVAGINAL first-trimester OB cases **with a demonstrable embryo or fetus** and their corresponding final reports. *Transabdominal images may be submitted as adjunct only.*

## From each additional site or mobile unit:

- submit 1 complete standard TRANSVAGINAL gynecologic case with its corresponding final report which include a demonstration and interpretation of the additional 3D images mentioned above

- and -

- if early OB exams are performed at the additional site or mobile unit, you must also submit 1 complete TRANSVAGINAL first-trimester OB case **with a demonstrable embryo or fetus** and its corresponding final report. *Transabdominal images may be submitted as adjunct only.*

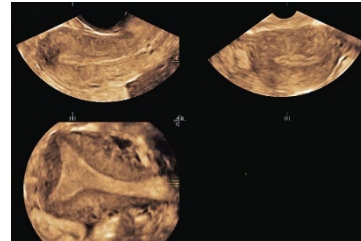
# REI with Adjunct 3D Imaging Checklists

## GYN with 3D

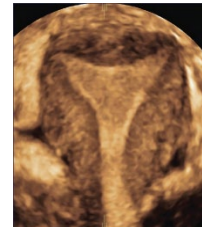
### Labeled images of the following:

- 1. Uterus – sufficient images to show orientation and rule out masses and other abnormalities (at least 2 orthogonal planes)
- 2. Uterus measured in 3 dimensions
- 3. Endometrium
- 4. Measurement of endometrium
- 5. Cervix
- 6. Cul-de-sac
- 7. RIGHT ovary measured in 3 dimensions obtained in 2 orthogonal planes
- 8. LEFT ovary measured in 3 dimensions obtained in 2 orthogonal planes

- 9. Acquisition image demonstrating the uterus in 3 orthogonal planes



- 10. Reconstructed CORONAL view of the uterus in a single image - this view should demonstrate the outer contour of the uterus and the inner endometrial shape



# REI with Adjunct 3D Imaging Checklists

## Standard OB – 1<sup>st</sup> Trimester

- **ALARA** – scans performed at less than 10 weeks GA should be done monitoring the Thermal Index for SOFT TISSUE (TIs).

### Labeled images of the following:

- 1. Uterus to determine location of gestational sac and rule out masses / abnormalities (at least 2 orthogonal planes)
- 2. Adnexal structures, even if ovaries not visualized
- 3. Cul-de-sac
- 4. Presence of embryo or fetus
- 5. Number of gestational sacs, embryos, or fetuses
- 6. Crown rump length
- 7. Demonstrate fetal heart rate using M-mode
- 8. If applicable, chorionicity and, if possible, amnionicity